

TOOLS OF THE TRADE – INTERVENTIONAL RADIOLOGY

Fei Sun

*Endoluminal Therapy and Diagnosis Department,
Jesús Usón Minimally Invasive Surgery Centre, Cáceres, Spain*

Interventional radiology refers to image-guided interventions characterized by minimal invasiveness. Technically, these interventions employ various tools introduced via percutaneous access or through natural orifices, navigating to the target organ, and finally deploying specific devices or delivering drugs for therapeutic purpose. Image-guided interventions rely heavily on instrumentation. Ensuring the proper selection of a particular instrument and making rational combinations of the tools and devices available is key to improving technical success, shortening procedure times, and avoiding potential complications. Knowledge of basic instrumentation is of great importance to the clinical practice of interventional radiology. Some of the more commonly used devices will be introduced in this chapter.

DIGITAL FLUOROSCOPY AND DIGITAL SUBTRACTION ANGIOGRAPHY

Digital fluoroscopy, also called digital radiography, is a computer-based digital image-processing technique by which real time radiographic images are projected on an image-intensifying fluorescent screen, and in turn converted or digitized for storage or reproduction through an image processor. Compared with conventional fluoroscopy, digital fluoroscopy has several advantages including: post processing that may greatly enhance contrast resolution, high speed image acquisition up to 30 frames/second, and digital image distribution and archiving.

In veterinary hospitals, the standard C-arm digital fluoroscopy system (Figure 1.1) is commonly located in an angiography suite or surgical operating room. It is a mobile and self-contained unit requiring no connections to other equipment. The image intensifier of the

C-arm unit normally comes in 23 or 30 cm (9 inch or 12 inch) sizes and can provide a sufficient field of view for interventional procedures in small animals. Advanced hardware and software upgrades may allow the traditional C-arm unit to meet the requirements for more contemporary clinical applications, including cardiovascular, neurovascular, and urological interventions. More advanced digital flat-panel detectors attached to the ceilings or floors are becoming more popular among larger referral veterinary centers.

Currently, digital subtraction angiography (DSA) has become an indispensable tool in angiography and endovascular interventions. DSA refers specifically to techniques by which an initial no-contrast mask image is electronically subtracted from subsequent serial images following injection of contrast medium into the target vessels. After subtraction, the static anatomic structure common to both images is removed; the remaining blood vessels containing contrast medium are opacified. DSA (Figure 1.2) substantially improves the contrast resolution of angiography; however, any slight motion of the structures inside the field of view during the image acquisition may induce remarkable artifacts greatly compromising the image quality. Accordingly, temporarily controlled apnea by suspension of mechanical ventilation is often recommended for abdominal angiography when performing DSA.

Roadmapping (also called trace subtract fluoroscopy) is the fluoroscopic equivalent of DSA. It is widely used to guide and facilitate endovascular manipulation of the catheter and guide wire. During the procedure, a desired background angiogram, with or without subtraction, is obtained. With the patient remaining perfectly still, the background angiogram is used as a mask to perform subtraction fluoroscopy (roadmapping) in the same field of view. In contrast to DSA, the contrast-filled vessel in roadmapping will appear

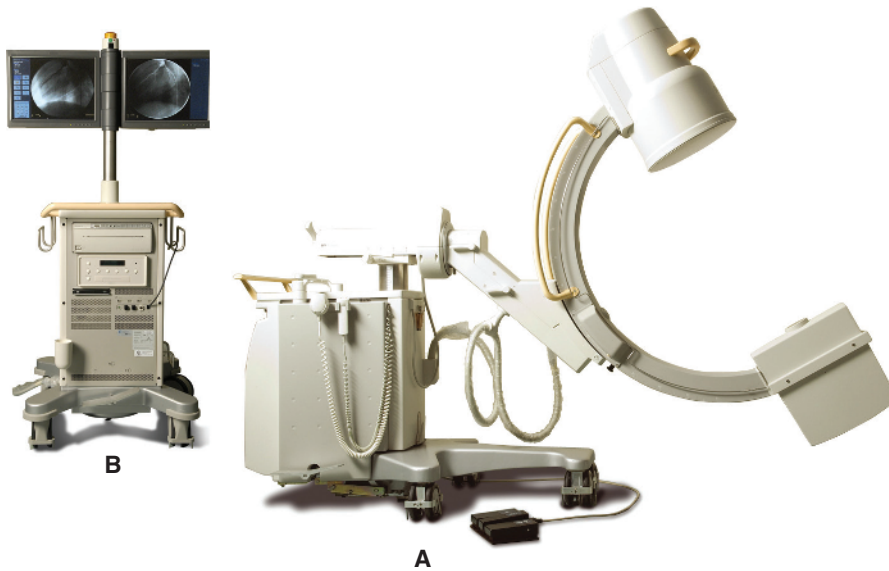


Figure 1.1 Mobile C-arm fluoroscopy system (BV Pulsera, Philips Medical Systems). (A) C-arm stand and imaging system; (B) mobile view station. Used with permission from Usón J, Sun F, Crisóstomo V, et al. (2010) Manual de técnicas endoluminales y radiología intervencionista en veterinaria. Jesús Usón Minimally Invasive Surgery Centre, Cáceres, Spain.

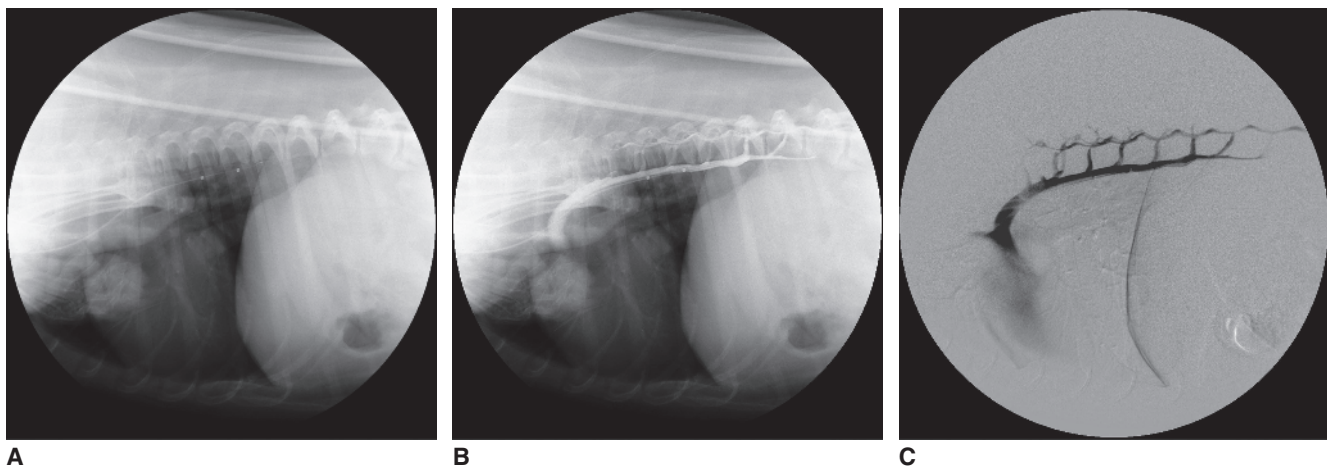


Figure 1.2 Selective digital subtraction angiography of the azygos vein (Lateral view). (A) mask image showing the background structures before injection of contrast medium; (B) The live or contrast image including azygos vein and surrounding anatomic structure; (C) digital subtraction angiogram of the azygos vein with background subtracted.

white, as opposed to black; images of a catheter and guide wire and their motion are visualized superimposed on the background mask image (Figure 1.3). Roadmapping may improve safety during catheter and guide wire manipulations, reduce radiation exposure and procedure times, and minimize contrast use.

Interventional radiology procedures may involve significant radiation exposure and associated risks for both staff and patients. Radiation protection is one of the main concerns in interventional radiology. For the operators and assistants, wearing an appropriate lead

apron, lead glasses and thyroid collar is essential; maintaining maximal distance from the radiation source whenever possible, is also important. Techniques to minimize radiation exposure include the use of low frame rate pulsed fluoroscopy, lower dose exposure (higher kV, lower mA) and the option of last-image-hold, use of the collimator when necessary, maximizing the source-to-patient distance, minimizing the air gap between the patient and the image intensifier/digital flat panel, and limiting the use of electronic magnifications.

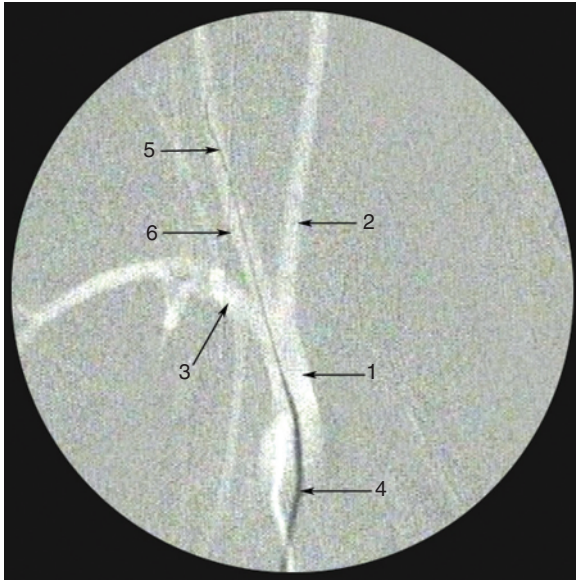


Figure 1.3 Roadmapping fluoroscopy as a guidance in manipulation of selective catheterization in the right common carotid artery. 1 – brachiocephalic trunk, 2 – left common carotid artery, 3 – right subclavian artery, 4 – angiographic catheter, 5 – guide wire, 6 – right common carotid artery. Used with permission from Usón J, Sun F, Crisóstomo V, et al. (2010) *Manual de técnicas endoluminales y radiología intervencionista en veterinaria*. Jesús Usón Minimally Invasive Surgery Centre, Cáceres, Spain.

ACCESS NEEDLES

Percutaneous access needles are thin-walled with relative large lumens to allow passage of the guide wire. The gauge system is used for sizing the outer diameter of access needles; higher gauge means thinner needle. Commonly used vascular access needles range from 18 to 21 gauge (G). For non-vascular access, a fine needle of 21 G is frequently used in order to minimize the damage to target organs. The lumens of needles may vary in size even if they are of the same gauge in outer diameter. Generally a 18G needle allows for passage of a 0.038" and 0.035" guide wire; a 19G needle, however, accommodates 0.035" but not 0.038" guide wires. Before puncturing, it is important to ensure that the guide wire to be used can pass through the needle.

The traditional vascular access needle, also called a Seldinger needle, consists of two parts. The outer metallic cannula has a blunt tip into which a pointed inner stylet is placed (Figure 1.4). Standard Seldinger needles are 18 G and 7 to 8 cm long. The use of Seldinger needles involves the double-wall puncture technique to achieve vascular access. Both walls of the target vessel are punctured with the needle assembly. After



Figure 1.4 Seldinger needle (18G) consists of an outer cannula and a pointed inner stylet. Used with permission from Usón J, Sun F, Crisóstomo V, et al. (2010) *Manual de técnicas endoluminales y radiología intervencionista en veterinaria*. Jesús Usón Minimally Invasive Surgery Centre, Cáceres, Spain.



Figure 1.5 Single-wall puncture needle (19G) is also called a one-part needle. Used with permission from Usón J, Sun F, Crisóstomo V, et al. (2010) *Manual de técnicas endoluminales y radiología intervencionista en veterinaria*. Jesús Usón Minimally Invasive Surgery Centre, Cáceres, Spain.

removal of the inner stylet, the needle cannula is retracted slowly until its blunt tip is back within the lumen of the vessel identified by blood return. A guide wire is inserted through the needle into the target vessel and vascular access can be subsequently obtained. Currently, the Seldinger needle is used less frequently due to the complexity of its two-part design and the concern of potential complications from double-wall puncture such as bleeding and damage to more proximal vessels during access.

Instead, a single-wall puncture technique is more frequently used. The single-wall needle has only one part, a metallic cannula with a sharply beveled tip without an inner stylet (Figure 1.5). This needle is designed for puncturing the more superficial wall of the target vessel. When the sharp needle tip pierces the wall and enters the vessel lumen, the blood return is identified. When puncturing a small artery, however, it is more difficult to position the needle tip totally within the arterial lumen by using the single-wall technique. If the beveled needle tip is partially placed in the lumen, insertion of the guide wire into the lumen is difficult or impossible so that meticulous repositioning of the needle is required. Either a double-wall technique is used or preferably a micropuncture set.

In small animal practice, a micropuncture set is most commonly used when accessing smaller vessels. The micropuncture set combines the use of a fine puncture needle and a standard guide wire. It consists of a 21 G puncture needle, an 0.018" guide wire, and a 4 or 5-Fr coaxial dilator assembly. The inner and outer coaxial

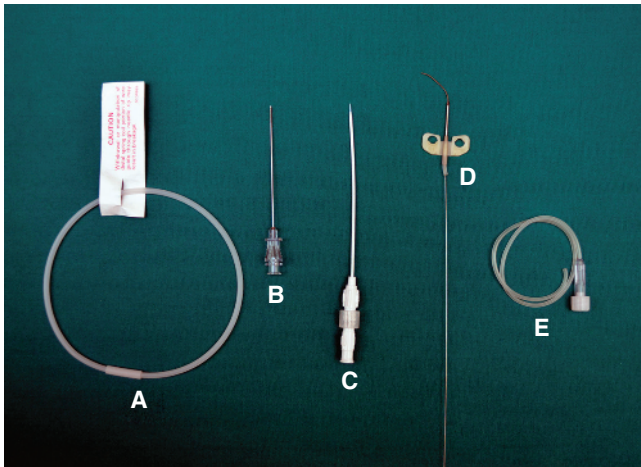


Figure 1.6 Vascular access by the use of butterfly infusion set (21 G). After the butterfly needle (D) punctures and enters the vessel, the silicon connection tube (E) is cut through which a 0.018" guide wire is inserted. The needle is removed and the microwire is replaced with a 0.035" wire using the coaxial dilators of a micropuncture set. A regular introducer sheath is inserted over the 0.035" wire. The micropuncture set includes 0.018" guide wire (A), 21G percutaneous needle (B), and coaxial dilators (C).

dilators accommodate an 0.018" and a 0.035" guide wire, respectively. During the procedure, the 0.018" guide wire is placed through the 21G needle and the coaxial dilators are placed over the guide wire. After removal of the 0.018" guidewire and the inner dilator leaving the outer dilator behind, a 0.035" guide wire can be placed through the outer dilator. In addition, the micropuncture set can be used in combination with the 22G IV catheter or a 21G butterfly infusion set (Figure 1.6). See Chapter 44 for more information on vascular access.

GUIDE WIRES

A guide wire is a device used to facilitate the placement of catheters at a particular target site. It serves two objectives during manipulations: selecting a desired route and offering support for advancing catheters. Although appearing rather simple and universal, guide wires are highly specialized medical instruments that play a vital role during interventions.

The outer diameter of guide wires is expressed in inches. The standard guide wires are 0.035" in diameter and 145cm in length. Guide wires of 0.038" are also commonly used and guide wires of 0.018" or less are called microwires. Guide wires should be selected to be twice as long as the catheters used in general. Exchange-length guide wires indicate those of 260cm




Figure 1.7 Guide wires (0.035") from the left to right: straight Glidewire, Rosen wire, Safe-T-J wire, curved Glidewire, and curved Roadrunner hydrophilic wire. Used with permission from Usón J, Sun F, Crisóstomo V, et al. (2010) Manual de técnicas endoluminales y radiología intervencionista en veterinaria. Jesús Usón Minimally Invasive Surgery Centre, Caceres, Spain.

or longer and allow for removal and replacement of longer catheters without losing selective access. Other characteristics of guide wires include tip shape, taper, core stiffness, and coating.

The soft leading tips of guide wires are available in straight, angled, and "J" configurations (Figure 1.7). Angled-tip guide wires are steerable for selective catheterization. Some microwires have a shapeable floppy tip made from shape memory alloy that enables the floppy tip to be deformed by the operator prior to use and maintains the user-shaped tip during manipulations. Furthermore, the deformed shape can be reshaped if the initial modification of the tip configuration is not ideal. J-tipped guide wires are designed for safety considerations as the J-curve tip is less traumatic when passing through tortuous vessels. The curve of the J tip is described by its radius with a range up to 15mm. The other advantage of the use of a J-tip guide wire is to avoid untoward entrance to branch vessels with diameters less than that of J-curve of the guide wire.

The length of taper is used to describe length of the distal flexible segment of the guide wire. It is constructed by a tapered mandrel core located within the central canal of guide wires, enabling a graduated transition from stiff to soft distal tip. The taper length of common guide wires ranges from 2cm (e.g., Rosen wire) to 20cm (e.g., Bentson wire). The size and stiffness of the mandrel determines the rigidity of guide wire shaft, which varies from regular or standard, stiff, extra stiff, super stiff to ultra stiff guide wires. Safe-T-J (Cook Medical) and Bentson (Cook Medical) wires have a standard stiffness of guide wire shaft. Terumo Glidewires and other

hydrophilic wires have two subtypes: standard and stiff guide wires. Rosen guide wires are of intermediate stiffness, which are stiffer than the stiff type of Terumo Glidewires. Guide wires in the Amplatz family (Amplatz Stiff, Amplatz Extra Stiff, Amplatz Super Stiff, and Amplatz Ultra Stiff guide wires) are stiffer than Rosen guide wires but not as stiff as Lunderquist guide wires. Generally, a guide wire with a longer taper is easy to negotiate tortuous vessels or a branch vessel with a steeply angled origin, whereas a stiffer guide wire affords more controlled catheter manipulation and enough support for passage of catheters, balloons or stents. In addition, guide wires with longer tapers, such as Bentson or Newton guide wires, are usually used as a pusher to deliver thrombogenic coils for embolization because a short taper stiff guide wire may deform the tip of catheter and flip it out the target vessel leading to dislodgement of the coil elsewhere.

Guide wire surfaces have many different coatings that convey various advantages. Most guide wires are coated with polytetrafluoroethylene (PTFE, Teflon®) and heparin to reduce friction and thrombogenicity. PTFE-coated guide wires increase lubricity during manipulations but have proved more thrombogenic than stainless steel guide wires. Accordingly, some guide wires come with double coatings, such as the PTFE-Coated Stainless Steel with Heparin Coating guide wire (Bentson, Cook Medical). Hydrophilic polymer coatings have been a major breakthrough in guide wire technology, and more recently have been applied in the manufacturing of catheters and other devices. A hydrophilic-coated guide wire has an extremely low coefficient of friction when wet. It can be passed into small, tortuous vessels more easily. Before introducing a hydrophilic guide wire into the body or passing a catheter over the guide wire, it must be completely wet and the catheter flushed. Otherwise, there is increased friction generated between the wire and the catheter. In addition, hydrophilic-coated guide wires have been reported to be significantly less thrombogenic than the stainless steel spring guide wires. Unlike conventional stainless steel guide wires, hydrophilic-coated guide wires (e.g., Terumo Glidewires or Infiniti Medical Weasel Wires), consist of a nitinol alloy core with a polyurethane jacket and a hydrophilic polymer coating. Due to the super elastic property of nitinol alloy these wires are highly resistant to kinking. This property provides both their advantage and their failing. Once a hydrophilic wire is advanced into a tortuous vessel, it may have a tendency to recoil out of the target vessel. To prevent the wire recoiling, especially when advancing a catheter over the guide wire, a constant forward force is needed to apply to the guide

wire by the use of a torque device. It is worth noting that the hydrophilic-coated guide wires should not be inserted or withdrawn through a beveled-tip needle or metal cannula because the hydrophilic coating may be sheared off leading to potential embolic debris.

INTRODUCER SHEATH

Once vascular access is achieved, an introducer sheath is typically placed. An introducer sheath (also called vascular sheath) is a thin-walled catheter placed percutaneously at the access site to facilitate insertion of catheters or other devices. An introducer sheath kit generally contains a dilator, sheath, and guide wire. The dilator is a thick-walled, stiff tube with a tapered leading end (Figure 1.8). Upon establishing percutaneous access, the coaxial dilator-sheath assembly is placed over the guide wire into the target vessel. Sheaths are labeled as French (Fr; 3 Fr=1mm) describing the inner diameters while dilators are named for the outer diameters. For example, a 5 Fr sheath can accommodate a catheter or dilator with maximal size of 5 Fr.

Vascular sheaths are most commonly used for two major purposes: protection of the vascular entry site and enabling exchanges of various catheters and other devices. Without the protection of the introducer sheath, the vascular wall at the entry site may be lacerated by repeated manipulations of catheters and other devices: e.g., twirling, advancing and withdrawing. A hemostasis valve and a side port are attached at the trailing end of the vascular sheath. The former enables



Figure 1.8 Check-flo introducer sheath (A), peel-away sheath (B), and guide wire (C). Used with permission from Usón J, Sun F, Crisóstomo V, et al. (2010) Manual de técnicas endoluminales y radiología intervencionista en veterinaria. Jesús Usón Minimally Invasive Surgery Centre, Cáceres, Spain.

exchanges of catheters, guide wires, and other devices without blood loss or air aspiration, while the latter allows pressure measurements, administration of heparinized saline, blood sampling, and injection of contrast medium.

Peel-away sheaths are another type of introducer sheath used in vascular or non-vascular procedures for implanting infusion or drainage catheters, pacemaker leads and other devices. The devices can be smoothly advanced into the desired location through the peel-away sheath. At completion of the procedure, the sheath is peeled off and removed, leaving the implanted devices in place.

ANGIOGRAPHIC CATHETERS

An angiographic catheter is a flexible conduit that allows delivery of contrast medium for angiographic diagnosis and administration of therapeutic agents or passage of other devices for endoluminal therapy. The catheter is composed of three parts: the hub, shaft, and tip. Angiographic catheters are measured in French for the outer diameter of the shaft. Most commonly used catheters are 4 or 5 Fr, accepting 0.035" or 0.038" guide wires. The length of commonly used catheters is between 65 and 100 cm.

Angiographic catheters are constructed of polyurethane, polyethylene, Teflon, or nylon with radiopaque materials in the wall. Polyethylene is commonly used in angiographic catheters. Polyethylene has a flexibility property that allows for easy passage of catheters over the guide wire to the target vessel with less damage to the intima. However, polyethylene catheters tend to soften with time at body temperature, and lose their shape memory and torsional rigidity after repeated manipulation. To enhance shape memory and torqueability, a fine wire mesh (braid) is usually incorporated into the wall of polyethylene catheters.

Polyurethane catheters are similar to polyethylene catheters in respect to good trackability (advancement over the guide wire). Compared with polyethylene, polyurethane is softer, more flexible, but less slippery (increased friction).

Teflon is occasionally used for flush catheters because of its moderate stiffness. Other features of Teflon include good memory, kink resistance, and lower coefficient of friction when wet. Currently, Teflon is generally reserved for use in dilators and sheaths.

Nylon catheters have reasonable stiffness and high tensile strength, and withstand high pressure and high flow injections. In addition, some angiographic catheters are treated with a hydrophilic polymer coating on




Figure 1.9 Angiographic catheters from the left to right: Cobra-II, Headhunter-I, Simmons-Sidewinder-I, and Pigtail catheters. Used with permission from Usón J, Sun F, Crisóstomo V, et al. (2010) Manual de técnicas endoluminales y radiología intervencionista en veterinaria. Jesús Usón Minimally Invasive Surgery Centre, Caceres, Spain.

the outer surface and substantially improve the trackability and reduce the risk of direct injury to the vessel.

Angiographic catheters are functionally divided into non-selective (flush) and selective categories (Figure 1.9). Flush catheters are commonly made of nylon or Teflon to allow for large-volume and high-pressure injections. They are straight or curled at the tip (pigtail catheter) with an end hole and typically 8 to 12 side holes. The pigtail tip keeps the end (hole) away from the vessel wall and multiple side holes along the distal shaft help evenly disperse contrast medium during injection without a single forceful jet effect that may cause unwinding of the looped tip or subintimal dissection. The side holes of flush catheters must be smaller than the end hole so that a guide wire accepted by the end hole cannot exit elsewhere.

All selective catheters share common criteria in design, including high torque control (torqueability), good radio-opacity, and adequate flexibility and trackability. The shape of the catheter tip varies greatly and is designed for specific functions. To selectively catheterize a target vessel, the catheter tip must be curved or angled. Some selective catheters can be used for many blood vessels; a particular blood vessel also can be cannulated by maneuvering various catheters with quite different shapes. Occasionally however, a slight change in the catheter tip configuration can make a big difference in the success or failure of a procedure. The shape of selective catheters can be simple or complex, depending on the number and fashion of curves at the leading end. The primary curve is defined as the one closest to the catheter tip. It is designed for seeking and engaging the origin of branch vessels. Additional

curves (secondary or tertiary) beyond the primary curve enable stabilization of the engaged catheter tip in the branch vessels and help to force the catheter tip deeper in position. Berenstein and Vertebral catheters are typical simple curve catheters. Cobra catheter is a double curve catheter, in which the primary and secondary curves are in the same direction. Recurvant catheters (reverse curve catheters) indicate that the primary and secondary curves are in opposite orientation. Examples of recurvant catheters are Simmons and Sos-selective catheters.

When recurvant catheters are introduced over a guide wire into the aorta they must be re-formed to their original packaged configuration prior to manipulation for selective catheterization. Generally, recurvant catheters will resume their original shape spontaneously provided there is sufficient space in the vessel lumen and shape-memory capability of the catheter. Otherwise, the Waltman loop technique and other strategies can be used to re-form the catheter shape. Once the tip of a recurvant catheter engages the orifice of target vessel, manipulations in moving catheter tip have the opposite maneuvering effects; inserting the trailing end of the catheter withdraws the leading tip from the vessel and pulling on it advances it further into the vessel. In addition, removal of a recurvant catheter from deeply selective position requires careful disengagement under fluoroscopic guidance. The curves of the recurvant catheter should be straightened with a guide wire prior to removal from the patient.

Most selective catheters only have an end hole, which snugly fits the accepted guide wire size. Some selective catheters, such as the Cobra catheter, have two small side holes immediately adjacent to the catheter tip. The design of side holes is to diminish risky high-velocity jet effects during injection of contrast with a power injector. However, side hole catheters should not be used for embolization. When delivering coils, side holes may entangle the coil at the catheter tip. Gelfoam and PVA particles also tend to occlude the catheter tip because of decrements in pressure distal to the side holes. Cautions should be exercised when using side hole selective catheters because thrombi can more easily form between the side hole and catheter tip. Catheters with suspected tip occlusion should be immediately removed.

BALLOON CATHETERS

Standard balloon catheters are wire-guided double lumen catheters that incorporate a balloon at the leading end. When a balloon catheter is inserted over

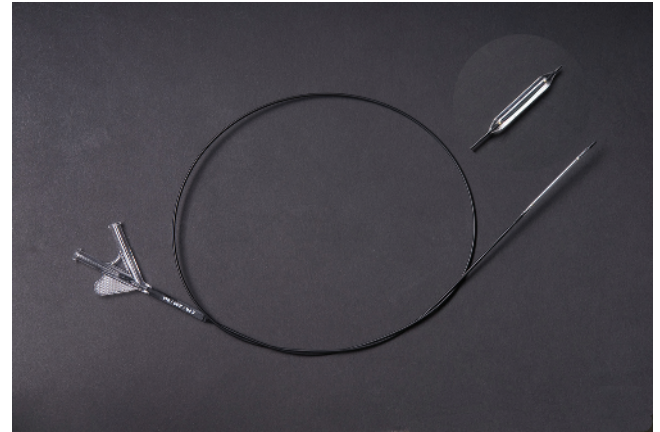


Figure 1.10 Angioplasty balloon catheter (5 Fr, 8 mm × 40 mm) before and after inflation. Used with permission from Usón J, Sun F, Crisóstomo V, et al. (2010) Manual de técnicas endoluminales y radiología intervencionista en veterinaria. Jesús Usón Minimally Invasive Surgery Centre, Cáceres, Spain.

a guide wire to a target site, the balloon can be inflated for therapeutic or diagnostic purposes. Two basic types of balloons are used in veterinary interventions: dilation and occlusion balloons. The dilation balloon is a high-pressure and non-elastic balloon used to apply force to dilate a local stricture, such as valvuloplasty in pulmonic stenosis (see Chapter 59) and esophageal dilation for benign esophageal strictures (see Chapter 13). The occlusion balloon is a low-pressure, elastomeric balloon and typically made of latex or silicone. Unlike dilation balloons, occlusion balloon inflation is guided by volume rather than pressure. In clinical practice, occlusion balloons are used for temporary occlusion of blood vessel to measure occlusive pressures or perform retrograde angiography.

Typical dilation balloons are composed of four parts: the tip, balloon, shaft, and hub (Figure 1.10). The balloon catheter tip should taper well to fit the guide wire and aid in crossing tight stenoses. The commonly accepted guide wires are 0.035 and 0.038 inch but lower profile balloons are available for use with smaller diameter wires (0.014" and 0.018" for example). The hub has two ports; the main central port is used for insertion of the guide wire and the side port is for inflation and deflation of the balloon. The shaft is described in Fr for its outer diameter and in centimeters for its length. A standard balloon consists of a cylindrical body, two conical tapers, and two necks (proximal and distal). The balloon is measured by millimeters in diameter and length. Balloon diameter refers to nominal inflated balloon diameter

measured at a specified pressure; balloon length refers to the working length or the length of the cylindrical body, typically indicated by a pair of radiopaque markers located underneath the balloon. Other technical details regarding inflation of the balloon include balloon nominal pressure (value at which the balloon reaches its labeled diameter), balloon rated burst pressure (value at which the probability of balloon rupture is 0.1%), and balloon average burst pressure (value at which the probability of balloon rupture reaches 50%).

Compliance is another important characteristic of a balloon catheter that describes the extent to which a balloon will stretch beyond a predetermined diameter when a certain force is applied. A low-compliance dilation balloon might expand only 5–10% when inflated to the rated pressure, whereas a high-compliance dilation balloon might stretch 18–30%. If the material is compliant, the balloon will deform in the region of a stenosis, in a dog-bone fashion. This prevents the dilating force from being concentrated in the narrowed lesion and tends to over-distend the adjacent normal vessel. Therefore, noncompliant balloons are desirable when dilating rigid stenotic lesions. Balloon compliance is determined by the material from which it is constructed. Nylon, polyester (PET), and polyurethane are the most common materials used in dilation balloon production. PET balloons offer high tensile strength and low compliance while polyurethane is softer and of medium to high compliance. Compliance of nylon balloons is medium between PET and polyurethane.

DRAINAGE CATHETERS

Percutaneous drainage catheters are commonly used for the management of various fluid collections: e.g., pleural and peritoneal drainage and lavage, nephrostomy and cystostomy drainage, and biliary drainage. Unlike angiographic catheters, drainage catheters are generally large bore (6–12 Fr), typically with a single large lumen allowing for a higher flow rate of viscous fluid. The tip of drainage catheters is designed with special configurations (pigtail or mushroom shape) to help prevent migration of the catheter (Figure 1.11). To enhance self-retention at the target site, a suture-locking-loop system is commonly used. The catheter has a suture passed through its proximal end and lumen. The distal end of suture is attached to the tip of the catheter. When the proximal end of suture is retracted, the distal pigtail is created. This configuration is

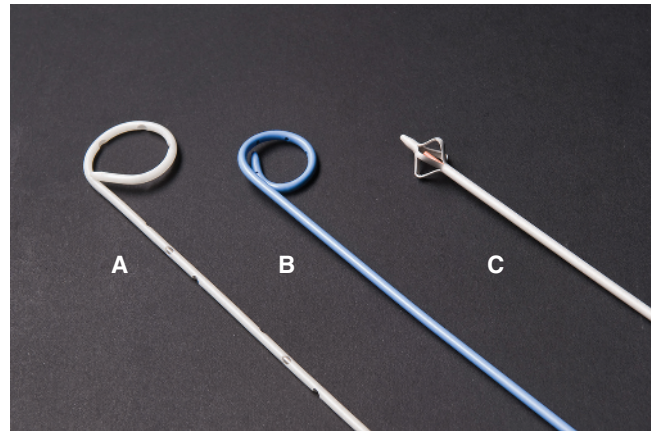


Figure 1.11 Common drainage catheters: biliary drainage catheter (A), nephrostomy drainage catheter (B), and Malcot nephrostomy catheter (C). Used with permission from Usón J, Sun F, Crisóstomo V, et al. (2010) *Manual de técnicas endoluminales y radiología intervencionista en veterinaria*. Jesus Usón Minimally Invasive Surgery Centre, Caceres, Spain.

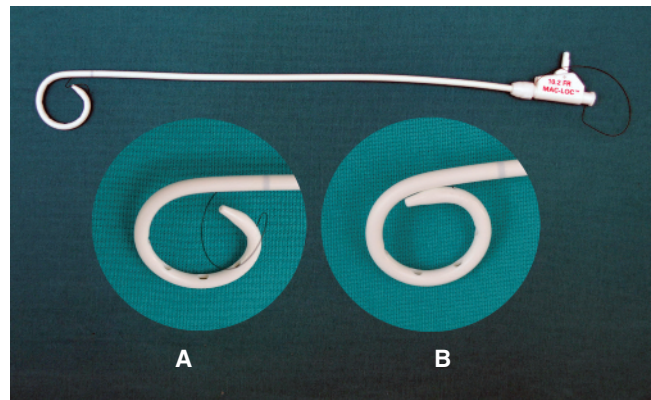


Figure 1.12 Mac-Loc[®] multipurpose drainage catheter (10.2 Fr, Cook Medical) with the distal loop before (A) and after locking (B).

maintained by a locking device at the hub of catheter. The locked pigtail protects against accidental dislodgement of the drainage catheter (Figure 1.12).

Typical drainage catheters (also called external drainage catheter) have multiple large side holes that are on the inside surface of the pigtail loop to maintain patency as the drained space surrounding the catheter collapses. Furthermore, the location of side holes at the inner aspect of the pigtail contains drainage to the target and decreases the likelihood of leakage back along the track, which potentially leads to infection and other complications. Some biliary drainage catheters are specially designed for purpose of internal/external drainage, with side holes extending several centimeters up to the catheter shaft so that they can be located above and below the obstruction

of lesion. This enable bile to pass from obstructed ducts above a stricture through the catheter to the duodenum (Figure 1.11).

Drainage catheters may be introduced percutaneously either by a direct puncture utilizing a trocar needle or by Seldinger technique. In general, superficial collections are drained by the trocar method, using the trocar stylet for direct insertion; in deeper collections with complex anatomy the Seldinger technique is preferable in the placement of a drainage catheter. Drainage catheters require periodic exchange. If access of the drainage site is to be maintained when exchanging catheters, a straight guidewire is used to past the distal tip of the pig-tail with less likelihood to exit a side hole because location of sideholes is on the inner curvature of the loop.

STENTS

Stents are tubular devices made of metal, plastic, or bioabsorbable materials that are implanted into blood vessels or other structures to restore or preserve luminal patency. Most stents are metal and commonly used for both vascular and nonvascular lesions, whereas plastic stents are only employed in some non-vascular organs such as the ureter, biliary duct, and trachea. Stents can be placed percutaneously or deployed through natural orifices with or without endoscopic assistance, such as in ureteral or tracheal stenting. Currently available metal stents are mostly made of nitinol or stain-less steel alloy by modern manufacturing technologies, including laser cutting, laser welding, and mechanical braiding. Differences in design and materials for stent fabrication directly influence the physical properties of the stent which can ultimately determine the technical success or failure of a procedure. Metal stents have two major categories including balloon-expandable and self-expanding stents. Based on coverings and coatings of metal stents they are further divided into bare stent (uncovered stent), stent-graft (covered stent), and drug-eluting stent (Figure 1.13).

A balloon-expandable stent (Figure 1.14) is a device used to perform dilation of a narrowed lumen and simultaneous implantation of a stent to support the wall, preserving long-term patency. The Palmaz stent was the first balloon-expandable stent and has undergone several modifications. Current balloon-expandable stents are constructed from a thin-walled stainless steel tube with parallel rows of staggered laser-cut slots. The stents are mounted onto a balloon catheter and placed across the target lesion. When the



Figure 1.13 Metal stents from the top to bottom: balloon-expandable stent, covered self-expanding stent, and uncovered self-expanding stent. Used with permission from Usón J, Sun F, Crisóstomo V, et al. (2010) Manual de técnicas endoluminales y radiología intervencionista en veterinaria. Jesús Usón Minimally Invasive Surgery Centre, Caceres, Spain.




Figure 1.14 Balloon-expandable stent before and after balloon inflation.

balloon is inflated, the rectangular slots open up to form diamond-shaped cells while the small tube is expanding into a cylindrical stent. After deflation and removal of the balloon catheter, the stent remains in place. Balloon-expandable stents have high radial force and hoop strength that resist deformation under a compressive load. They are most commonly used in stenting arterial ostial stenosis in humans. Other advantages of balloon-expandable stents include ease of implantation at a precise location and a precise stent diameter controlled by final inflation of the balloon at an indicated pressure. However, if an outer compressive force (beyond the stent's yield point) is applied to an implanted balloon expandable stent, it will be

crushed with irreversible deformation (plastic deformation). Thus, balloon-expandable stents should not be used in locations where they may be compressed by external forces due to repetitive motion such as in the neck or over joints. Relative lack of flexibility and short length is another drawback of balloon-expandable stents, so that they cannot be readily deployed across bifurcations or in tortuous vessels. During the stenting procedure, a guiding catheter or guiding sheath is always recommended when advancing the stent-balloon device to the target site in order to avoid dislodgement of the un-deployed stent. Balloon-expandable stents are most commonly used in veterinary medicine for nasopharyngeal stenosis (see Chapter 6).

Self-expanding stents are compressed within a delivery system and generally divided into mesh/woven types or laser-cut types. They are implanted by retracting the outer sheath while holding the stent delivery system in place. The exposed part of the stent, due to its spring-like tendency, immediately expands to reach its nominal diameter. To ensure secure fixation, most stents require oversizing 1–2 mm (or more) greater than the target lumen. The Wallstent (mesh stent) is a special self-expanding stent that is composed of 18 to 24 Elgiloy stainless steel filaments, each 100 μm in diameter, woven in a crisscross pattern to form a tubular braid configuration. The filament crossing points are not fixed but are free to slide or pivot over each other. The special design allows the stent to be flexible, compressible and have a good radio-opacity. Another common example of a mesh stent is the Infiniti Medical nitinol Vet Stent-Trachea. One feature of most mesh stents is the reconstrainable nature of the delivery system. If the stent is partially released but at an undesirable position, the stent may be reconstrained at a variable percentage of its total length (up to 87% in the Wallstent) until its limit marker band (“point of no return”) and repositioned or removed. However, caution should be exercised concerning the foreshortening of mesh stents. Stent foreshortening refers to the shortening of the stent that occurs as its diameter increases upon deployment. Foreshortening of mesh stents is substantial and can vary between 20% and 50% according to the final expansion during deployment. These mesh stents are most commonly used in veterinary medicine for tracheal stenting (see Chapter 7), GI stenting (see Chapter 17), and vascular stenting (see Chapters 21 and 49).

Currently, the most commonly used self-expanding stents in humans are laser-cut nitinol stents. Nitinol (an acronym for Nickel Titanium Naval Ordinance Laboratories) is an alloy composed of approximately 55% nickel and 45% titanium (wt.%), which has been found to have unique properties of shape memory and

super-elasticity. Nitinol stents are magnetic resonance imaging (MRI) compatible and produce fewer artifacts than stainless steel stents. More importantly, laser-cut nitinol stents exhibit minimal foreshortening during deployment compared to mesh stents, and have a more predictable length and location after deployment. Common veterinary examples of laser-cut nitinol stents are the Infiniti Medical Vet Stent-Urethra or Vet Stent-Cava. It should be noted that some (Symphony stent) nitinol stents may exhibit significant foreshortening. Unlike stents made from laser-cut nitinol tubes, the Symphony stent is constructed from nitinol wire welded to form a closed-cell structure. Reported foreshortening of the Symphony stent may be up to 11.7%. Laser-cut stents are not typically reconstrainable making removal extremely difficult and not recommended, especially during deployment. Laser-cut stents are most commonly used in veterinary medicine for urethral tumors (see Chapter 34) and in the vasculature (see Chapters 21 and 49).

Fabric-covered stents or stent-grafts and drug-eluting stents are also available in balloon-expandable and self-expanding types. In human medicine, vascular covered stents are used for exclusion of aneurysms or management of arterial rupture; non-vascular covered stents are used for malignant strictures. Drug-eluting stents have been developed to minimize post-procedural vascular restenosis by local delivery of drugs that block cell proliferation. Covered stents are uncommonly used in veterinary practice but have been used in the urinary tract (see Chapter 31), nasopharynx (see Chapter 6), gastrointestinal tract (see Chapter 17), and vasculature (see Chapter 21).

A typical plastic stent used in veterinary practice is the ureteral stent composed of synthetic polymeric compounds including polyurethane, silicone and other proprietary polymeric materials. Functionally, it works as an internal drainage catheter designed with multiple sideholes and two pigtail-loop ends (also called double-pigtail stent) (Figure 1.15). To minimize the possibility of migration one loop is deployed within the renal pelvis and the other within the urinary bladder. Endoscopic implantation of the stent is the standard technique in dogs, whereas surgical stent placement is needed in patients without endoscopic access and cats typically (see Chapter 30). Some stents have a hydrophilic coating in order to decrease friction and reduce or eliminate biofilm formation and encrustation. The Vet Stent-Ureter (Infiniti Medical) stents are dedicated for veterinary use and come in a variety of sizes (2.5–6.0 Fr) and lengths (12–23 cm); the inner lumens of the stents accommodate various sized guide wires (0.018–0.035 inch).

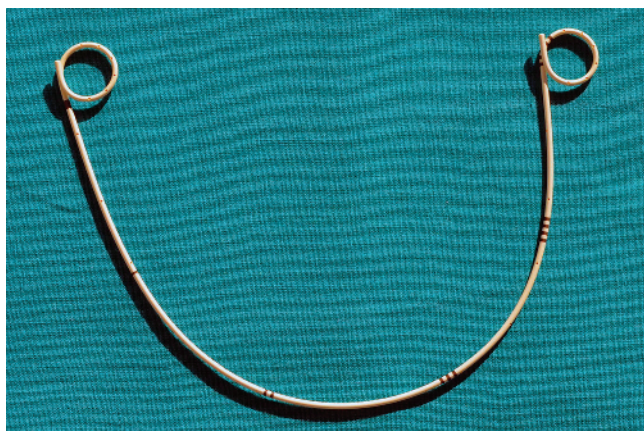

Figure 1.15 Universa™ double pigtail stent (4.7 Fr, Cook Medical).

COILS

Metallic coils are most frequently used for occlusion of abnormal vascular communications including portosystemic shunts (see Chapter 21) and patent ductus arteriosus (PDA) (see Chapter 58). The first-generation coil, Gianturco Coil, was initially developed by Drs. Gianturco and Wallace in 1975, which was comprised of a short stainless steel wire with diameter ranging from 0.025" to 0.038" packaged in a straight conformation within an introducer. When the coil is delivered into the target vessel, it assumes a spiral or other configuration with specified diameter and length. In theory, the deployed coils do not occlude the vessel lumen completely but rather induce thrombosis. To enhance thrombogenicity, the coil was subsequently modified by attaching wool strands or synthetic fibers (Figure 1.16). Newly developed MReye Embolization Coils (Cook Medical) are constructed of Inconel super alloy, which has similar physical characteristics to stainless steel, but has no ferro-magnetic properties. The coils are easily detected radiographically and are considered to be MRI compatible, with the potential for minor artifacts to be observed in the immediate vicinity of the device. Selection of proper coil size is extremely critical during coil embolization. Generally, the diameter of the deployed coil should be approximately 2 mm larger than that of target vessel. When the coil is too small, it may migrate distally, even into the pulmonary circulation through arteriovenous shunting if present. Conversely, if the coil is too large, it cannot retain its normal form, so that the proximal elongated portion protrudes out of the target vessel. Since the 1990s, smaller coils made of platinum have been available. The small platinum coils come in 0.010 to 0.018 inch in diameter and can be delivered through microcatheters

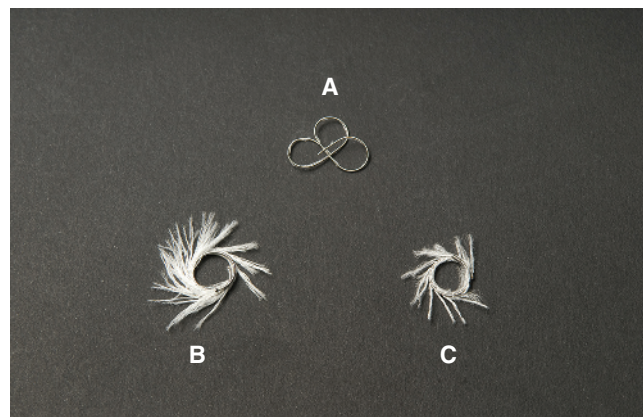


Figure 1.16 Coils with different size and shape with synthetic fibers: (A) complex helical fibered platinum coil-18 (Boston Scientific); (B) MReye-35 coils (Cook Medical); (C) fibered platinum coil-35 (Boston Scientific). Used with permission from Usón J, Sun F, Crisóstomo V, et al. (2010) Manual de técnicas endoluminales y radiología intervencionista en veterinaria. Jesús Usón Minimally Invasive Surgery Centre, Caceres, Spain.

to embolize tiny vessels. To control precise coil implantation and minimize the risk of coil migration, detachable coils (e.g., MReye Flipper coils by Cook Medical), have been widely used in occlusion of PDAs.

AMPLATZ CANINE DUCT OCCLUDER

The Amplatz Canine Duct Occluder (ACDO, Infiniti Medical) is a self-expanding nitinol mesh device intended for endovascular closure of canine PDAs. The ACDO is specifically designed to fit the size and shape of the canine PDA. It has a short central waist that connects a flat distal disk and a cupped proximal disk (Figure 1.17). After implantation, the distal disk covers the pulmonary artery side of the ductal ostium, the waist spans the pulmonic ostium of the ductus, the dense nitinol mesh occludes the communication, and the proximal cupped disk expands and conforms to the shape of the ductal ampulla. The ACDO device is available in a wide range of waist sizes (3 mm–14 mm) that can meet the needs for closure of any size PDA. However, application of the ACDO is limited by the size of patient. In dogs under 2.5 kg of body weight the femoral artery is too small to accommodate the appropriate catheter size. Additionally, if the length of ductus is too short (e.g., the window type PDA), the ACDO is contraindicated because of the risk of interference with the aortic flow. The ACDO is recapturable (reconstrainable) before release and repositionable to



Figure 1.17 Amplatz Canine Ductal Occluder connecting to a delivery cable. (Copyright Infiniti Medical, LLC, Menlo Park, CA, USA.)

obtain a final stable and desired position improving technical success and safety. Furthermore, the transarterial approach used for ACDO placement makes selective placement of the device through the ductus much easier and avoids right heart catheterization and its associated complications such as arrhythmia and kinking of the device sheath. Since the development of the ACDO, this device has gained widespread popularity and become the treatment of choice for the majority of PDA occlusions. See Chapter 58 for more information on PDA occlusion.

SUMMARY

Interventional procedures are indeed a process of maneuvering, threading, passing, and delivering a variety of special tools or medications to target organs for diagnostic and therapeutic purposes. Familiarity and proper selection of the optimal devices, as well as awareness of potential complications associated with their use are essential for any veterinarian performing these procedures.

SUGGESTED READING

Berent AC, Weisse C, Beal MW, Brown DC, Todd K, and Bagley D (2011) Use of indwelling, double-pigtail stents for treatment of malignant ureteral obstruction in dogs: 12 cases (2006–2009). *J Am Vet Med Assoc* 238(8), 1017–25.

- Berent AC, Weisse C, Todd K, Rondeau MP, Reiter AM (2008) Use of a balloon-expandable metallic stent for treatment of nasopharyngeal stenosis in dogs and cats: six cases (2005–2007). *J Am Vet Med Assoc* 233(9), 1432–40.
- Estrada A, Moïse NS, Renaud-Farrell S (2005) When, how and why to perform a double ballooning technique for dogs with valvular pulmonic stenosis. *J Vet Cardiol.* 7(1), 41–51.
- Gonzalo-Orden JM, Altónaga JR, Costilla S, et al (2000) Transvenous coil embolization of an intrahepatic portosystemic shunt in a dog. *Vet Radiol Ultrasound* 41, 516–518.
- Gordon SG and Miller MW (2000) Transarterial coil embolization for canine patent ductus arteriosus occlusion. *Clin Tech Small Anim Pract* 20(3), 196–202.
- Leach KR, Kurisu Y, Carlson JE, et al (1990) Thrombogenicity of hydrophilically coated guide wires and catheters. *Radiology* 175(3), 675–7.
- Nakagawa N, Yashiro N, Nakajima Y, Barnhart WH, and Wakabayashi M. (0000) Hydrogel-coated glide catheter: experimental studies and initial clinical experience. *AJR Am J Roentgenol* 163(5), 1227–9.
- Reddy SC, Kamath P, Talwar KK, Saxena A, and Wasir HS (1997) Guide wire outer coat shearing and embolisation: an unusual complication of pericardiocentesis. *Int J Cardiol* 60(1), 15–8.
- Rösch J, Keller FS, and Kaufman JA (2003) The birth, early years, and future of interventional radiology. *J Vasc Interv Radiol* 14(7), 841–53.
- Singh MK, Kittleson MD, Kass PH, and Griffiths LG (2012) Occlusion devices and approaches in canine patent ductus arteriosus: comparison of outcomes. *J Vet Intern Med* 26(1), 85–92.
- Spinosa DJ, Angle JF, Hagspiel KD, Pyle DA, and Matsumoto AH (1998) Iliac artery stenting: A review of devices and technical considerations. *Appl Radiol* 27(7), 10–24.
- Sun F, Usón J, Ezquerro J, Crisóstomo V, Luis L, and Maynar M (2008) Endotracheal stenting therapy in dogs with tracheal collapse. *Vet J* 175(2), 186–93.
- Tanaka R, Hoshi K, Nagashima Y, Fujii Y, and Yamane Y (2001) Detachable coils for occlusion of patent ductus arteriosus in 2 dogs. *Vet Surg* 30(6), 580–584.
- Weisse C, Berent A, Todd K, Clifford C, and Solomon J (2006) Evaluation of palliative stenting for management of malignant urethral obstructions in dogs. *J Am Vet Med Assoc* 229(2), 226–34.
- Weisse C, Berent AC, Todd KL, and Solomon JA (2008) Potential applications of interventional radiology in veterinary medicine. *J Am Vet Med Assoc* 233(10), 1564–74.
- Weisse C, Schwartz K, Stronger R, et al (2002) Transjugular coil embolization of an intrahepatic portosystemic shunt in a cat. *J Am Vet Med Assoc* 221, 1287–91.