How to Perform the Neurological Examination

CHAPTER 1

Simon R. Platt[1] and Susan A. Arnold[2]

[1] *Department of Veterinary Clinical Sciences, College of Veterinary Medicine, Oklahoma State University, Stillwater, OK, USA*
[2] *Department of Veterinary Clinical Sciences, University of Minnesota, St. Paul, MN, USA*

The main components of the neurological examination can be divided into an observation portion and a hands-on portion (Table 1.1). The results of the examination can be recorded in a standardized neurological examination form (Table 1.2). This form can be downloaded for use in your clinic or hospital using this QR code.



General observation of mental status and behavior, gait, and posture can be performed while taking the history, but may necessitate changing the clinical environment, waiting for the patient to become comfortable with their new surroundings, or going outside. Based on the presenting complaint, it may be necessary to modify portions of the examination. For example, a patient that is non-ambulatory after being hit by a car is not subjected to postural reaction testing for fear of exacerbating a possible unstable vertebral fracture.

Table 1.1 An overview of the components of the neurological examination.

The observation portion of the examination includes:
(i) Evaluation of mental status and behavior
(ii) Evaluation of gait
(iii) Evaluation of the patient's posture
The hands-on components of the examination include:
(i) Postural reactions
(ii) Cranial nerve evaluation
(iii) Spinal reflex evaluation
(iv) Palpation
(v) Pain perception (reserved for patients demonstrating plegia)

0006199418.INDD 1 07/31/2026 4:24:49 PM

Table 1.2 Neurological examination sheet.

Veterinary Neurological Examination Form

Pet

Owner

Pet Species

Pet Breed

Pet Age (years)

Pet Weight (kg)

Reason for Examination / Presenting Symptoms

Level of Consciousness

- ◯ Alert
- ◯ Dull
- ◯ Stuporous
- ◯ Comatose

Posture

- ☐ Left Head Tilt
- ☐ Right Head Tilt
- ☐ Left Head Turn
- ☐ Right Head Turn
- ☐ Wide-Based Stance
- ☐ Nerve root Signature
- ☐ Kyphosis / Scoliosis
- ☐ Ventroflexed neck
- ☐ Palmigrade / Plantigrade
- ☐ Schiff-Sherrington
- ☐ Decerebellate
- ☐ Decerebrate

Table 1.2 (Continued)

Gait

- ☐ Normal
- ☐ Hypermetria
- ☐ Ambulatory Paraparesis
- ☐ Non-Ambulatory Paraparesis
- ☐ Paraplegia
- ☐ Hemiplegia
- ☐ Ataxia
- ☐ Hypometria
- ☐ Ambulatory Tetraparesis
- ☐ Non-Ambulatory Tetraparesis
- ☐ Hemiparesis

Cranial Nerve Assessment

	Left	Right
Menace Response (II, Cerebrum, VII)		
Dazzle (II, Thalamus, VII)		
Pupillary Light Reflex (II, III)		
Palpebral Reflex (V, VII)		
Corneal Reflex (V, VI)		
Physiological Nystagmus (III, IV, VI, VIII)		
Nasal Stimulation (V, Forebrain)		
Gag Reflex (IX, X)		
Tongue Size and Movement (XII)		
Jaw Tone (V)		
Masticatory Muscle Mass (V)		
Other Observations		

(*Continued*)

Table 1.2 (Continued)

Postural Reactions

	Left Thoracic	Right Thoracic	Left Pelvic	Right Pelvic
Proprioceptive Positioning				
Hopping				
Wheelbarrow / Extensor Postural Thrust				
Visual Placing				
Tactile Placing				

Spinal Reflexes

	Left	Right
Extensor Carpi Radialis		
Thoracic Withdrawal		
Patellar		
Cranial Tibial		
Gastrocnemius		
Pelvic Withdrawal		
Cutaneous Trunci		
Perineal		

Pain Assessment

	Left Thoracic	Right Thoracic	Left Pelvic	Right Pelvic?	Tail Head / Perineal
Nociception					

Lesion Localization

OBSERVATION OF THE PATIENT

MENTAL STATUS AND BEHAVIOR

Before handling the patient, let the patient explore the examination room, if ambulatory, and observe the patient's reaction to the surroundings (Video 1.1). Mental status should be evaluated in terms of both the level of consciousness and the patient's behavior.

VIDEO 1.1 Allowing the patient to roam around the consulting room or a protected space outside can provide insight into the animal's level of consciousness, reaction to stimulation, and behavior. This normal dog demonstrates exploratory behavior as well as a bright and alert demeanor.

Level of Consciousness

- Normal/alert – the patient responds appropriately to environmental stimuli.
- Depressed/obtunded – the animal is drowsy but arousable. Depressed/obtunded dogs and cats are typically inattentive and display little spontaneous activity.
- Stuporous – the patient is unconscious, but arousable with a strong (typically painful) stimulus.
- Comatose – the patient is unconscious and cannot be aroused even with painful stimuli.

Patient Behavior

The patient may have a normal level of consciousness but exhibits abnormal behavior and responds inappropriately to stimuli. Abnormal behavior is identified by comparing the patient's behavior to expected behavior for animals of a similar breed and age (Video 1.2). The owner/caretaker is often able to bring subtle changes in behavior to the veterinarian's attention.

VIDEO 1.2 A 5-year-old Dalmatian dog is seen to exhibit compulsive pacing with a reduced level of consciousness from that expected in a normal dog and confusion as suggested by getting "stuck" in corners.

POSTURE

Posture is the position of the body with respect to gravity. Abnormal postures, such as a head tilt or wide-based stance, are common in dogs and cats with neurologic disease.

Several classic abnormal postures indicative of neurologic dysfunction have been described.

- Abnormal head position is often manifested as a head tilt or a head turn. In a patient with a head tilt, one ear is held lower than the other and the eyes are not parallel to the floor. Unilateral vestibular dysfunction will often cause a head tilt. In a patient with a head turn, the head is held with eyes parallel to the ground , but the nose is turned right or left, indicating intracranial disease, most often prosencephalic.
- Decerebrate rigidity is due to a brainstem lesion causing recumbency and is characterized by extension of all limbs, occasionally with opisthotonus (dorsiflexion of the head and neck) (Figure 1.1). A decreased level of consciousness (often stupor or coma) usually accompanies this posture.
- Decerebellate rigidity is due to an acute cerebellar lesion and is also characterized by recumbency with opisthotonus, thoracic limb extension, and flexion of the hips (Figure 1.2). Consciousness is not impaired due to a lack of brainstem involvement.
- Schiff–Sherrington posture is caused by an acute lesion in the thoracic or lumbar spinal cord segments. Extension of the thoracic limbs with paralysis of the pelvic limbs characterizes Schiff–Sherrington posture (Figure 1.3).



FIGURE 1.1 An 11-year-old miniature poodle exhibits recumbency with rigidity of all four limbs and extension of the neck compatible with decerebrate rigidity and opisthotonus. The dog was in a coma on presentation.



FIGURE 1.2 A 7-year-old Yorkshire terrier with an inflammatory disease predominantly affecting the cerebellum exhibits a spastic flexion of the pelvic limb with increased extensor tone in the thoracic limbs and the cervical musculature, compatible with decerebellate rigidity. This patient had normal mentation.



FIGURE 1.3 A 4-year-old terrier mix presented with acute flaccid paralysis and extensor rigidity of the thoracic limbs secondary to an acute thoracolumbar intervertebral disc extrusion. This is compatible with the Schiff–Sherrington posture.

GAIT

Several abnormalities of gait can be observed. These include lameness, ataxia, paresis or paralysis, and involuntary movements.

Lameness

Lameness is decreased leg function, making walking difficult, and is often associated with pain. Such pain can cause limb dysfunction when the patient tries to bear weight on it, resulting in reduced weight bearing and rapid use of the contralateral limb to relieve the pain. As a result, the stride of the painful limb is often shortened. When a single limb is severely painful, it is often carried. This is in contrast to a paretic limb (see next), which is often dragged. Lameness is usually caused by orthopedic, musculoskeletal, or regional vascular disease and by some neurologic lesions, such as inflammation of a nerve root, compression of the nerve root by an intervertebral disc extrusion, or a neoplasia such as a nerve sheath tumor. This neurogenic type of lameness is often referred to as a "root signature."

Patients with bilateral limb pain, such as hip disease or ruptured cruciate ligaments, may not walk at all or have short-strided, stilted gaits. This can mimic weakness due to neurologic disease.

Ataxia

This is the inability to perform normal, coordinated motor activity that is not caused by weakness, musculoskeletal problems, or abnormal movements, such as tremor. There are three types of ataxia.

- **Proprioceptive ataxia**
  This is associated with the loss of the sense of limb and body position due to interruption of ascending proprioceptive pathways (primarily unconscious proprioception). It is caused by a lesion affecting the general proprioceptive pathways in the peripheral nerve, dorsal nerve root, spinal cord, and brainstem.

  It is characterized by clumsiness and incoordination, resulting in a wide-based stance and a swaying gait of the body. The stride of the affected limb(s) is often longer than normal, and the toes may drag or scuff the ground (Video 1.3).



VIDEO 1.3 A 9-year-old dachshund with a thoracolumbar myelopathy exhibits mild proprioceptive ataxia of the pelvic limbs, especially noted when the dog makes a turn.

- **Cerebellar ataxia**
  This is the inability to regulate the rate and range of movement (unconscious proprioception) and is characterized by dysmetria, especially hypermetria, which is an overreaching, high-stepping gait (Video 1.4). Cerebellar ataxia is caused by cerebellar disease or selective dysfunction of spinocerebellar tracts (less common).



VIDEO 1.4 A young American Staffordshire terrier exhibits a hypermetric ataxia affecting all four limbs, compatible with cerebellar dysfunction.

- **Vestibular ataxia**
  Unilateral vestibular lesions cause an ataxia that is accompanied by leaning and falling to one side (Video 1.5). Other signs of vestibular disease, such as head tilt and abnormal nystagmus, may be evident. A severe form of this type of ataxia can result in rolling while recumbent. With bilateral vestibular dysfunction, the patient maintains a crouched position, is reluctant to move, and exhibits side-to-side head movements.



VIDEO 1.5 A young Chihuahua exhibits a left-sided head tilt, a wide-based stance with a leaning and falling ataxia to the left, compatible with vestibular ataxia.

Paresis/Paralysis

Paresis is a partial loss of voluntary movement, while paralysis (plegia) is a complete loss of voluntary movement (Videos 1.6–1.9). Paresis or paralysis indicates a lesion of either the upper motor neuron (UMN) system or the lower motor neuron (LMN) system (see lesion localization chapter). It is not possible to discriminate between UMN and LMN dysfunction based solely on severity, but UMN and LMN dysfunction result in different qualities of gait abnormality. UMN dysfunction leads to spastic, stiff movements, whereas LMN dysfunction leads to weak, short movements. Further, a loss of ability to support weight is a feature of LMN disease, and an inability to generate gait is a feature of UMN disease.



VIDEO 1.6 A mixed-breed dog exhibits non-ambulatory tetraparesis secondary to a C1–C5 myelopathy. There is plegia of the thoracic limbs (no motor function) and paresis of the pelvic limbs (some motor function noted). The increased tone noted in the limbs is compatible with an upper motor neuron lesion.



VIDEO 1.7 A Weimaraner with a C6–T2 myelopathy exhibits ambulatory tetraparesis. There is a short stride in the thoracic limbs and a long stride in the pelvic limbs.



VIDEO 1.8 An 11-year-old dachshund exhibits ambulatory paraparesis and proprioceptive ataxia secondary to a T3–L3 myelopathy.



VIDEO 1.9 A 3-year-old domestic long-haired cat exhibits non-ambulatory tetraparesis secondary to a polyneuropathy. There is carpal flexion and a generalized loss of tone in the limbs.

Abnormal Movements

There are many types of abnormal, involuntary movements. Those that can occur constantly rather than episodically include tremors, myoclonus, and myotonia.

- Tremor – a rhythmical, oscillatory movement localized to one region of the body or generalized to involve the entire body. Tremors can be classified by their distribution and frequency, as well as whether the problem occurs at rest, with posture, on action, or with intention

  Resting tremors: These are observed when the affected body part is supported against gravity and is not voluntarily activated. This form of tremor has not been reported in dogs and cats. The best example of a resting tremor in people would be the tremor associated with Parkinson's disease.

  Action-related tremors: These are diffuse, high-frequency skeletal muscle tremors that worsen with activity and resolve with sleep.

  Postural tremors: These occur during voluntary maintenance of a position against gravity (e.g. a tremor of the limbs when standing that dissipates on activity or lying down). Examples of these include (1) orthostatic tremors, (2) idiopathic head tremor syndrome, and (3) benign, idiopathic, rapid postural tremor (Video 1.10).



VIDEO 1.10 An older beagle dog exhibits high-frequency, low-amplitude pelvic limb tremors. This was only noted when the dog was standing and is compatible with a benign, idiopathic, rapid postural tremor seen in older dogs.

  Kinetic tremors: These occur during any aspect of voluntary movement. They can be present when the movement begins, during the course of movement, and as the target is reached. These are often termed intention tremors most commonly seen as a tremor of the head and neck that occurs when focusing on something such as a food bowl. They are associated with cerebellar disorders and as such, other localizing signs (e.g. hypermetria, disequilibrium) can also be present.

- Myoclonus – this may be physiological (e.g. hiccups or movements on falling asleep referred to as hypnic jerks) or pathological. A common method for classifying pathological myoclonus is by its neuroanatomical localization, subdivided into cortical, subcortical (brainstem and spinal

cord), and peripheral types. However, this is not always intuitive, and it has been proposed that myoclonus can also be classified according to its association with epilepsy as an epileptic myoclonus or as a non-epileptic myoclonus. An example of a non-epileptic myoclonus is constant repetitive myoclonus. This is a constant rhythmic jerking, usually of one limb every 1 to several seconds, which persists during activity, rest, and sleep, and may involve several limbs or muscles such as the diaphragm or masticatory muscles.

- Myotonia – this is a delayed relaxation of muscle following voluntary contraction. Myotonia is manifested as muscle stiffness that is relieved by exercise. Attacks of myotonia may culminate in recumbency with rigid extension of the limbs. Some patients with myotonia will display "dimpling" of sustained indentation of affected muscle when percussed.

THE HANDS-ON EXAMINATION

POSTURAL REACTION TESTING

The primary aim of testing postural reactions is to detect any subtle deficits that were not obvious on gait evaluation. Postural reactions test proprioception. Proprioception is the awareness of the precise position and movements of the body and especially the limbs. Proprioceptors are specific receptors sensitive to these movements. They are located in the joint, tendon, and muscles (general proprioception), as well as in the inner ear (special proprioception). The information collected by these receptors is transmitted to the cerebral cortex, where it is consciously perceived (conscious proprioception).

Proprioception involves complex pathways but generally includes an afferent arc and an efferent arc:

The afferent arc: This consists of a proprioceptive receptor, a peripheral sensory nerve, the spinothalamic ascending pathways, and the contralateral somatic sensory area of the cerebral cortex (integration center) (Figure 1.4).

The efferent arc: This consists of the motor cortex contralateral to the tested limb, descending motor pathways within the brainstem and spinal cord (UMN pathways), and the peripheral motor nerve (LMN pathway), as well as the skeletal effector muscles.

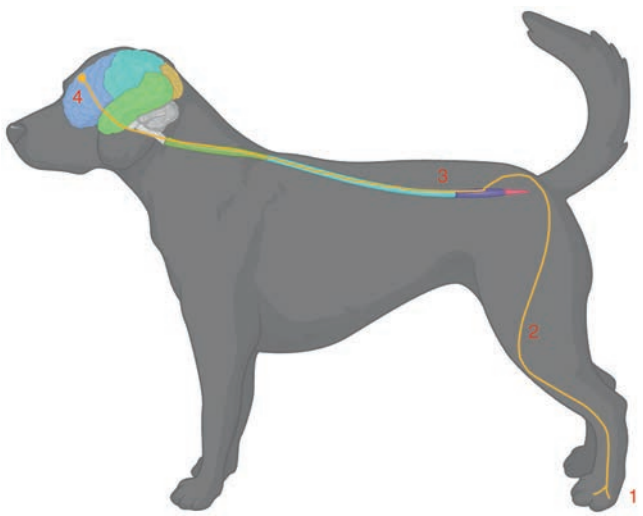

FIGURE 1.4 An illustration of the afferent arc of the conscious proprioceptive pathway. This consists of a (1) proprioceptive receptor, (2) a peripheral sensory nerve, (3) the spinothalamic ascending pathways, and (4) the contralateral somatic sensory area of the cerebral cortex (integration center). Source: Created with www.biorender.com.

Lesions affecting any of the aforementioned anatomical sensory and motor components could result in abnormal postural reactions; therefore, the tests are not very discriminatory for lesion localization purposes. The importance of testing them is in the detection of subtle dysfunction and asymmetries, as well as confirming that a neurological disease is present. In general, postural reactions remain normal in neuromuscular junction and muscular diseases, as long as the animal has the strength to support its weight.

Proprioceptive placing: This is the most commonly performed test in the dog and is designed to evaluate the conscious awareness of the limb position and its movement. It is particularly difficult to perform in cats, which resent having their feet handled during proprioceptive positioning, and so an alternative test is most often performed in this species (see next).

Conscious proprioception is evaluated by placing the paw in an abnormal position (turned over so that the dorsal surface is in contact with the ground) and determining how quickly the animal corrects the paw position (Video 1.11). When performing this test, the animal should be standing squarely on all four limbs, and it is fundamental to support the majority of the animal's weight in order to improve test sensitivity. Failure to do so causes flexion of the limb, which results in the stimulation of many proprioceptors within the different flexed joints. Supporting their weight is also helpful for animals that are reluctant to bear weight because of a painful limb (as seen with some orthopedic diseases). The test should be repeated until the examiner is confident with the result.



VIDEO 1.11 As the patient is supported, the digits can be turned over to test proprioceptive positioning. A normal response is seen in this dog with a rapid replacement of the foot to the standing position.

Hopping: This test is the preferred postural reaction test in cats. It can be particularly difficult to perform in large breeds of dog. The hopping reaction is tested by holding the patient so that the majority of its weight is placed on one limb while the animal is moved laterally (Video 1.12). Normal animals hop on the tested limb to accommodate a new body position as their center of gravity is displaced laterally. An equal response should be seen on both sides, and a normal response consists of hopping the limb before it is located past midline toward the contralateral side of the limb being tested. Subtle ataxia or weakness of one limb may be detected. Animals with severe orthopedic disease will have difficulty performing this test unless their weight is supported adequately.



VIDEO 1.12 Hopping the patient on each of its legs laterally is another test of proprioception. This can be achieved by lifting the animal up completely and letting it bear weight on the tested limb, or in larger patients, simply by picking the contralateral limb up and gently pushing the animal away to initiate the hop. A quick pick up of the paw and a smooth placement of the paw into the weight-bearing position should be seen.

Placing response: Visual placing and tactile placing are, in principle, much more complex postural reaction tests. They are mainly used when proprioceptive positioning or hopping reactions do not confirm a disorder. Visual placing can also be useful in assessing visual function in an animal where the menace response or obstacle course testing is difficult to interpret. Tactile placing is tested with the animal's eyes covered. The animal is lifted, and the distal part of the thoracic limb is brought in contact with the edge of a table. When the dorsal surface of the paw makes contact with the edge of the surface, the animal should immediately place its foot on the surface. Visual placing is tested by allowing the animal to see the table surface. Normal animals will reach for the surface before the paw touches the table.

Hemiwalking, extensor postural thrust, and wheelbarrowing: These are also more complex postural reaction tests.

- *Wheelbarrowing tests the thoracic limbs:* The animal's pelvic limbs are lifted off the ground by supporting the animal under the abdomen and forcing it to walk forwards. This test highlights

subtle thoracic limb weakness and ataxia. Subtle vestibular dysfunction can be detected by extending the animal's head and neck while testing.

- *Extensor postural thrust tests the pelvic limbs:* It is elicited by supporting the animal by the chest caudal to the thoracic limbs and lowering the pelvic limbs to the floor, forcing it to walk backwards, thus testing pelvic limb weakness and ataxia.
- Hemiwalking tests the ability of the animal to walk on the thoracic and pelvic limbs on one side while holding the limbs on the other side. The animal should be pushed away from the side on which its limbs are supported and the speed and coordination of the movements assessed. This is best performed on a nonslip surface.

CRANIAL NERVE ASSESSMENT

Tests of cranial nerve (CN) function are summarized in Table 1.3. The following is an overview of each cranial nerve's function, clinical evaluation, and signs of dysfunction. Testing of these nerves

Table 1.3 Cranial nerve function and testing.

Cranial nerve	Nerve Target / Function	Applicable tests
I Olfactory	Smell	Blindfold the animal and monitor behavioral response to food placed near the nose; loss of smell is usually due to nasal disease rather than neurological disease.
II Optic	Vision	i. Menace response ii. Pupillary light reflex iii. Obstacle course iv. Dropping cotton wool balls in front of each eye
III Oculomotor	Extrinsic and intrinsic ocular muscles/upper eyelid muscle	i. Eyeball position ii. Pupil size (mydriatic in disease) iii. Physiological nystagmus iv. Pupillary light reflex
IV Trochlear	Extrinsic ocular muscles	i. Eyeball position
V Trigeminal	Facial sensation/ jaw movement	ii. Palpebral reflex iii. Jaw and masticatory muscle palpation
VI Abducent	Extrinsic ocular muscles	i. Eyeball position ii. Physiological nystagmus
VII Facial	Muscles of facial expression/ parasympathetic supply to lacrimal glands	i. Palpebral response ii. Evaluation of facial symmetry iii. Schirmer tear test
VIII Vestibulocochlear	Hearing and balance	i. Oculocephalic reflexes ii. Assessment for head tilt
IX Glossopharyngeal	Muscles of the pharynx and larynx	Gag reflex
X Vagus	Muscles of the larynx and pharynx	Gag reflex
XI Accessory	Superficial neck muscles	None applicable
XII Hypoglossal	Muscles of the tongue	Tongue grab/inspection

should be done in conjunction with the assessment of proprioception and mentation to determine whether there is brainstem (central) disease or peripheral cranial nerve disease.

OLFACTORY NERVE – CN I

Anatomy and function: CN I is involved in the conscious perception of smell. It is a unique sensory cranial nerve in that its cell bodies lie in the olfactory epithelium on the ethmoturbinate bones rather than in a ganglion. Its axons pass through the cribriform plate to synapse with secondary neurons in the olfactory bulb. These secondary neurons pass successively into the olfactory peduncle and olfactory tracts before they synapse with third-order neurons in the olfactory tubercle. This final neuron projects to the piriform lobe in the olfactory region of the brain.

Clinical evaluation: Evaluation of smell is difficult in animals and remains a subjective assessment. As such, it is rarely performed in clinical cases. This sensory function can be assessed by testing the animal's response (sniffing or licking of the nose, aversion of the head) to aromatic substances while blindfolded. Care should be taken not to use irritating substances that could stimulate the trigeminal nerve (CN V) and cause similar responses.

Clinical signs of dysfunction: Decreased or absent sense of smell is defined as hyposmia or anosmia, respectively. Detecting deficits in smell is difficult and often based on historical findings (e.g. decreased appetite). Non-neurological causes (such as rhinitis and other nasal diseases) are more common causes than central nervous system (CNS) disease.

OPTIC NERVE – CN II

Anatomy and function: The optic nerve is not a "true" nerve but an extension of the brain. It is part of the central visual pathway (involved in sensory visual perception) and the afferent component of the menace response and pupillary light reflex (PLR).

The visual pathway involves three consecutive neurons (see Chapter 6).

- The first neuron represents the bipolar cells of the retina and receives visual information from the neuroepithelial cells of the retina (e.g. rods and cones).
- The second neuron corresponds to the ganglion cell of the retina. Its axon lies in the optic nerve and continues through the optic chiasm and proximal part of the optic tract on the opposite side (55% decussation in humans, 66% in cats, and 75% in dogs).
- The third neuron has its cell body in the lateral geniculate nucleus in the thalamus. Its axon projects to the visual cortex (mostly contralateral occipital cortex) in a band of fibers called the optic radiations.

The menace response is a cortically mediated blink produced by a threatening or unexpected image suddenly appearing in the near visual field. It is present from about 10–12 weeks of age in dogs and cats. The afferent part of this response involves the same structures as the visual pathways. The information generated in the visual cortex is forwarded to the motor cortex to initiate a motor response. The corticobulbar pathways to the facial nerve nucleus (CN VII) then transmit the motor information. This response requires intact facial nerve function and an intact cerebellum (ipsilateral function). The neuronal pathways through the cerebellum are not known.

The afferent part of the PLR shares some common pathways (up to the level of the optic tract) with the visual pathways. While axons involved in vision reach the conscious level after synapse with the lateral geniculate nucleus of the thalamus, the axons involved in the PLR

synapse with a third neuron in the pretectal nucleus of the dorsal midbrain. Most of the axons arising from this nucleus decussate again and synapse in the parasympathetic component of the oculomotor nucleus (ipsilateral to the stimulated eye), also in the midbrain. There are also neurons that do not decussate and that project to the oculomotor nucleus on the contralateral side to the stimulated eye. The majority of axons decussate, and this explains why the direct response (constriction in the eye receiving the light stimulus) is greater than the consensual response (constriction in the eye not receiving the light stimulus). The efferent arm of the PLR involves parasympathetic axons in CN III (oculomotor), causing constriction of the pupil.

Clinical evaluation: The optic nerve is the common component of the afferent pathways involved in vision, menace response, visual placing, and the PLR. These tests use different integration centers within the brain and different efferent pathways. The integrity of the optic nerve can be determined by combining the results of these tests.

- Vision in animals is evaluated by observing the animal navigating around the examination room.
- In dogs, the menace response is tested by making a threatening gesture toward the eye via the extreme visual fields (temporal and nasal, which project to different cortical hemispheres), while the other eye is covered; closure of the eyelids should be observed (Video 1.13). In cats, however, it is preferable to stand behind the animal with the contralateral eye uncovered, as up to 40% of cats with vision fail to have a menace response when the contralateral eye is covered. If unilateral visual loss is suspected, each eye can be blindfolded in turn prior to completion of an obstacle course.



VIDEO 1.13 In dogs, the menace response is often performed when standing in front of the patient. One eye is shielded, and the other eye is threatened with an open or closed hand without trying to create a current of air that can be felt by the patient. The normal response is a rapid blinking of the eyelids with a slight avoidant movement of the head.

- At the time of the PLR, the pupils should be examined for symmetry. Resting pupils should be equal in diameter, although slight differences are insignificant. Unequal pupil size is called anisocoria. When performing the PLR examination, a bright light is shined into one eye at a time (Video 1.14). Both pupils should constrict, with a direct response in the tested eye being slightly stronger than a consensual response in the opposite eye. When a bright light is initially flashed into the eye, a blink response may occur. This is referred to as the dazzle reflex and probably does not involve the cerebrum but rather thalamic nuclei. If a poor quality light source is used, the stimulated pupil may dilate slightly with continued stimulation. This is referred to as pupillary escape.



VIDEO 1.14 The pupillary light reflex is performed by shining a bright light into each eye and monitoring the response of the ipsilateral and contralateral pupil for the direct and consensual response, respectively.

Clinical signs of dysfunction: Lesions of the optic nerve can be manifest as partial or complete loss of vision and/or dilated and unresponsive pupils.

OCULOMOTOR NERVE – CN III

Anatomy and function: CN III innervates the ipsilateral dorsal, ventral, and medial recti (extraocular) muscles as well as the ventral oblique muscle (Figure 1.5). The oculomotor nerve also plays an important role in the efferent arm of the PLR and eyelid movement. It is involved in

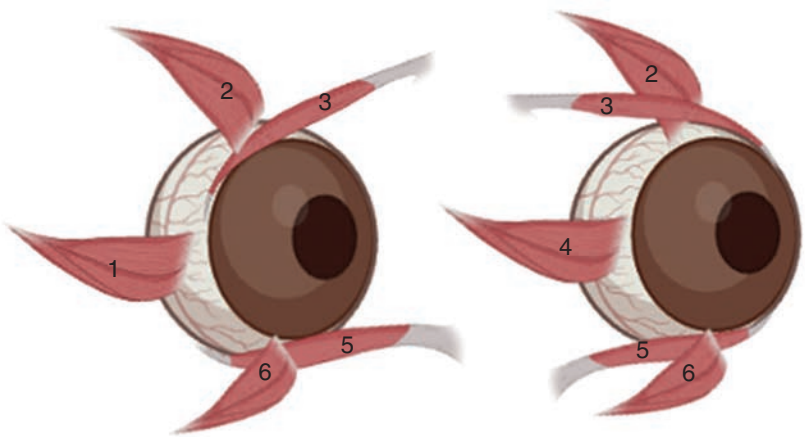

FIGURE 1.5 The extraocular muscles of the eyes are innervated by one of the three cranial nerves (III, IV, and VI). (1) Lateral rectus – VI, (2) dorsal rectus – III, (3) dorsal oblique – IV, (4) medial rectus – III, (5) ventral oblique – III, and (6) ventral rectus – III. The retractor bulbi (VI) is not visible in this illustration. *Source:* Created with www.biorender.com.

the elevation of the upper eyelid (levator palpebrae superioris) and controls pupillary constriction via its parasympathetic component. The oculomotor nuclei are located in the rostral midbrain. Their axons exit the brainstem and traverse the middle cranial fossa lateral to the hypophysis before they exit the skull through the orbital fissure.

Clinical evaluation: CN III function can be assessed by observing eye position and movements at rest and by testing for normal physiological nystagmus (vestibulooocular reflex) by moving the head from side to side and up and down (see Vestibulocochlear nerve – CN VIII) (Video 1.15). The parasympathetic function of CN III can be assessed by observing the pupil size and evaluating the PLR.

VIDEO 1.15 Physiological nystagmus is tested by moving the patient's head from one side to the other, as well as up and down. The response of each eye is assessed for a normal response, which is a rapid movement to the side of the head turn and a slow movement back to the center of the gaze.

Clinical signs of dysfunction: Lesions of the oculomotor nerve produce a ventrolateral strabismus and an inability to rotate the eye dorsally, ventrally, or medially during oculovestibular testing (external ophthalmoplegia). This strabismus must be differentiated from a vestibular strabismus that only occurs in certain head positions and is termed positional strabismus. The aforementioned signs can also be associated with a dilated unresponsive pupil (referred to as internal ophthalmoplegia) and/or narrowing of the palpebral fissure (ptosis of the upper eyelid). However, any of these signs can exist on their own.

TROCHLEAR NERVE – CN IV

Anatomy and function: CN IV innervates the contralateral dorsal oblique muscle. This muscle is responsible for the inward rotation of the eyeball. The trochlear nucleus is located in the caudal midbrain. After leaving the brainstem, its axons decussate on the dorsal surface of the brainstem and course rostrally through the middle cranial fossa before they exit the skull via the orbital fissure.

Clinical evaluation: As for CN III, CN IV can be assessed by observing the eye position at rest and by testing for normal physiological nystagmus.

Clinical signs of dysfunction: Lesions of the trochlear nerve produce a dorsolateral strabismus (extorsion) of the contralateral eye. In dogs, this is best evaluated by fundoscopic examination, observing temporal deviation of the dorsal retinal vessels. In cats, it can be seen as an alteration in pupil orientation. This is a very rare isolated finding: lesions of this nerve usually occur in combination with CN III and CN VI lesions, producing complete internal and external ophthalmoplegia.

TRIGEMINAL NERVE – CN V

Anatomy and function: CN V provides sensory innervation to the face (cutaneous elements of the face and the cornea, mucosa of the nasal septum, and mucosa of the oral cavity) and motor innervation of the masticatory muscles (temporalis, masseter, medial and lateral pterygoid, and rostral part of the digastric muscles). The cell body of the sensory part of CN V lies in the trigeminal ganglion. Its sensory nuclei form a large, separate, continuous, and elongated nuclear column extending along the brainstem. Its motor nuclei are located in the pons. CN V consists of three branches: ophthalmic, maxillary, and mandibular. Each branch provides sensation to specific areas of the face:

- Ophthalmic (cornea, medial canthus of the eye, nasal septal mucosa, and skin on the dorsum of the nose)
- Maxillary (lateral canthus of the eye, skin of the cheek, side of the nose, muzzle, palates, mucous membrane of the nasopharynx, teeth, and gingiva of the upper jaw)
- Mandibular (mandibular portion of the face and oral cavity)

The ophthalmic and maxillary branches are in close proximity to the cavernous sinus before they exit the skull through the orbital fissure and round foramen, respectively. These two branches have only sensory function. The mandibular branch exits the skull through the oval foramen and serves both a motor and sensory function.

Clinical evaluation: The motor function of CN V is assessed by evaluating the size and symmetry of the masticatory muscles and testing the resistance of the jaw to opening the mouth. The sensory function (sensation of the face) can be individually tested by:

- The corneal reflex (ophthalmic branch) – this is performed with a cotton-tipped applicator lightly applied to the surface of the cornea. Sometimes it is necessary to distract the palpebrae with your fingers to ensure that they do not close while you are attempting this reflex. When the stimulation is applied to the cornea, the eyeball is seen to retract, and the eyelids close.
- The palpebral reflex (ophthalmic or maxillary branch when touching the medial or lateral canthus of the eye, respectively) – both the medial and lateral canthus of each eye are touched with the finger, and in response, there should be a rapid and complete closure of the eyelids (Video 1.16).



VIDEO 1.16 The palpebral reflex is tested by touching both the medial and lateral canthi with the response being closure of the eyelids.

- The response to stimulation of the nasal mucosa (ophthalmic and maxillary branches) – as another way to assess head and face sensation and behavioral reaction to cranial stimulation, a blunt instrument or cotton-tipped applicator is gently inserted into each nostril while trying to

blindfold the animal with the other hand. A normal response to this stimulation is an immediate retraction of the head from the stimulus (Video 1.17).



VIDEO 1.17 Nasal stimulation tests the ophthalmic branch of the trigeminal nerve (CN V) and cortical response to obnoxious stimuli. It is not a reflex, but a behavioral response, similar to the menace response. A withdrawal of the head away from the stimulus is the expected normal response.

- Pinching the skin of the face with hemostat forceps and observing an ipsilateral blink or facial twitch.

A reflex response is best distinguished from a conscious response by stimulating the nasal mucosa: the normal animal will pull its head away, while the animal with forebrain disease may blink or show a facial twitch, but not show a conscious reaction.

Clinical signs of dysfunction: Unilateral involvement of the motor part of CN V causes ipsilateral masticatory muscle atrophy and decreased jaw tone. Enophthalmia and protrusion of the third eyelid can be observed in the ipsilateral eye (passive retraction of the eyeball due to the loss of the temporalis muscle mass). Bilateral involvement of the motor branches produces a dropped jaw with inability to close the mouth voluntarily, associated with various degrees of masticatory muscle atrophy depending on the duration of signs. Decreased or complete loss of facial sensation is defined as facial hypoesthesia or anesthesia. Involvement of the ophthalmic branch of CN V can also produce decreased tear secretion and neurotropic keratitis secondary to the loss of afferent stimulation to the lacrimal reflex.

ABDUCENT NERVE – CN VI

Anatomy and function: CN VI innervates the ipsilateral lateral rectus and retractor bulbi muscles. The CN VI nucleus is located in the rostral medulla oblongata. Its axons follow the same pathway as the axons of CN III and CN IV. The abducent nerve leaves the cranial cavity through the orbital fissure.

Clinical evaluation: CN VI function can be assessed by observing the eye position and movement at rest, testing for normal physiological nystagmus, and testing for normal eyeball retraction during the corneal reflex.

Clinical signs of dysfunction: Lesions of the abducent nerve result in an ipsilateral convergent strabismus, an inability of the eye to cross the midline when evaluating the horizontal physiological nystagmus, and an inability to retract the eyeball. Isolated lesions are rare, as for CN IV.

FACIAL NERVE – CN VII

Anatomy and function: CN VII provides motor function to the muscles of facial expression and sensory function (providing the sense of taste) to the rostral two-thirds of the tongue and palate. Its parasympathetic component innervates the lacrimal glands and the mandibular and sublingual salivary glands. Neurons innervating the muscles of facial expression are located in the facial nucleus in the rostral medulla oblongata. The axons pass through the internal acoustic meatus of the petrosal bone on the dorsal surface of the vestibulocochlear nerve and leave the skull through the stylomastoid foramen. The facial nerve courses through the middle ear before branches are distributed to the muscles of facial expression (ear, eyelids, nose, cheeks, and lips) as well as the caudal portion of the digastric muscle. The parasympathetic fibers (which produce lacrimal gland secretion) leave the facial nerve as it courses through the middle ear.

Clinical evaluation: The motor function of CN VII is primarily assessed by observing the face for symmetry (position of the ears and lip commissure on each side within the same plane, symmetry of the palpebral fissure), spontaneous blinking, and movement of the nostrils. The facial nerve also provides the motor response (efferent part) of the following tests:

- Palpebral reflex (CN V and VII)
- Corneal reflex (CN V, VI and VII)
- Menace response (CN II and VII)
- Pinching of the face (CN V and VII) – the lip pinch is evaluated by pinching the upper lip at the level of the canine tooth using a hemostat. The afferent sensory impulse travels along the infraorbital nerve (a branch of the maxillary branch of the trigeminal nerve, CN V). The efferent response is mediated by the facial nerve (CN VII).

The Schirmer tear test can evaluate the parasympathetic supply of the lacrimal gland associated with CN VII. Examining the mouth for a moist mucosa can subjectively assess salivation.

Clinical signs of dysfunction: Motor dysfunction of CN VII produces ipsilateral drooping of and inability to move the ear and lip, widened palpebral fissure and absent spontaneous and provoked blinking, absent abduction of the nostril during inspiration, and deviation of the nose toward the normal side due to the unopposed muscle tone on the unaffected side. With chronic denervation, the lips are retracted further than normal and the nostril is deviated to the affected side as a result of muscle fibrosis.

Facial spasm can also be seen, causing retraction of the lips and nostril to the affected side, and narrowing of the palpebral fissure on the affected side. This can be distinguished from chronic denervation by performing the palpebral test: in facial spasm the eye can blink.

Unilateral involvement can be seen in the asymmetry of the ears, eyelids, lips, and nose. Lesions of the individual branches of the facial nerve along their course produce paresis or paralysis of the specific muscles they innervate. Dysfunction of the parasympathetic supply of the lacrimal gland produces keratoconjunctivitis sicca. This is mainly seen with lesions of the facial nerve located between the medulla and the middle ear. Lesions distal to the facial canal in the temporal bone will not affect these parasympathetic neurons.

VESTIBULOCOCHLEAR NERVE – CN VIII

Anatomy and function: The vestibulocochlear nerve is involved in hearing and vestibular function (adaptation of the position of the eye and body with respect to the position and movement of the head).

The vestibular system consists of special proprioceptors within the petrous temporal bone (inner ear) (Figure 1.6A), the vestibular nerve, and four brainstem nuclei located in the rostral medulla oblongata on each side of the fourth ventricle. The receptor organs (saccule, utricle, and semicircular canals) detect the position and movement of the head. The neurons of the vestibular ganglia receive impulses from these receptors and project into the vestibular nuclei via the internal acoustic meatus, where this special proprioceptive information is integrated. The vestibular nuclei connect to the nuclei of the cranial nerves responsible for eye movement (CN III, IV, and VI) via the medial longitudinal fasciculus. They also project to the ipsilateral extensor muscles of the limb via the vestibulospinal tract. Finally, these neurons project to the ipsilateral flocculonodular lobe of the cerebellum via the caudal cerebellar peduncles. Through these pathways, the vestibular system controls the position of the eyes, trunk, and limbs depending on the position and movements of the head.

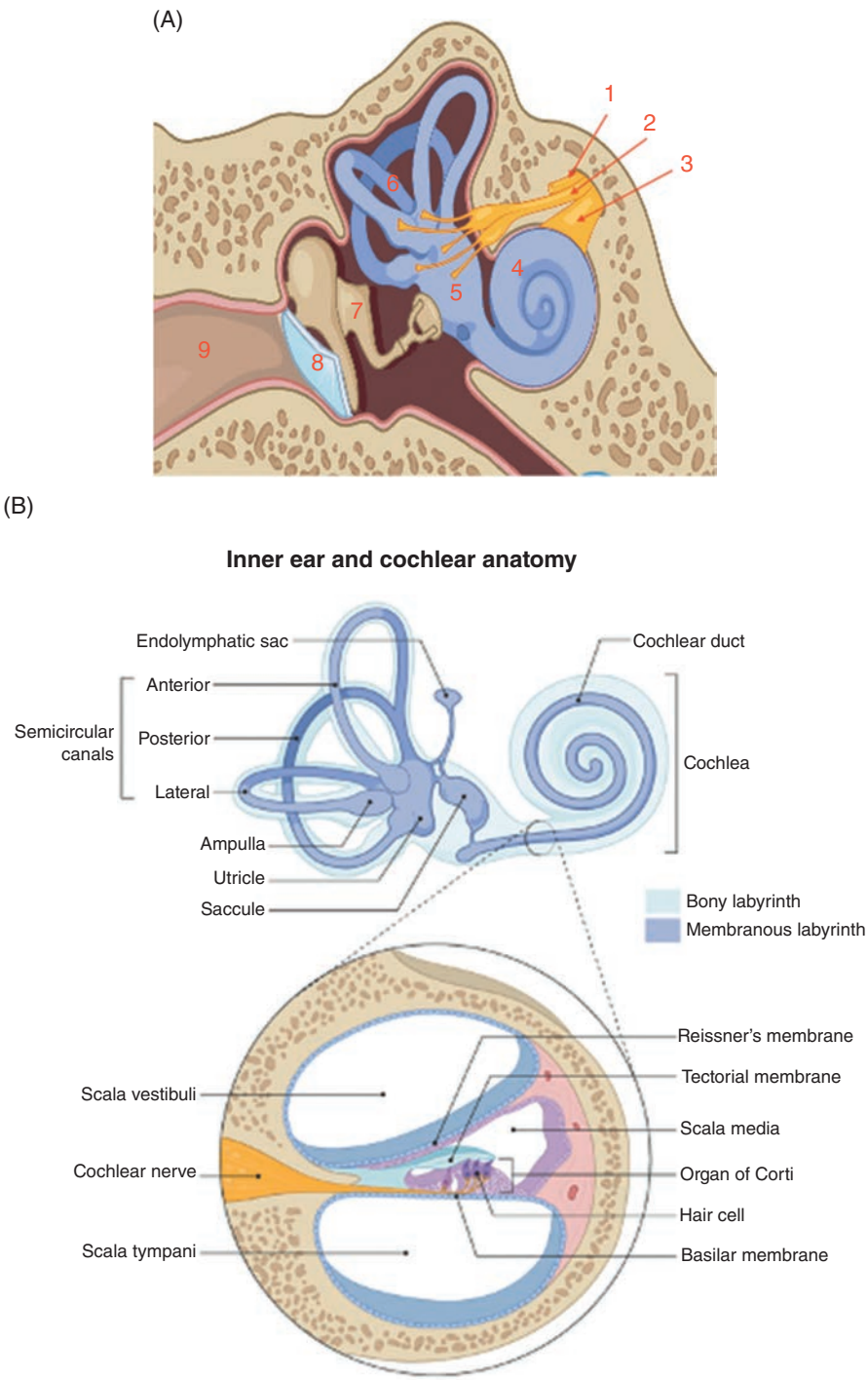

FIGURE 1.6 The peripheral components of the vestibular system originate in the petrous temporal bone and are adjacent to the receptors for auditory function within the inner ear. (A) (1) Facial nerve, (2) vestibular nerve, and (3) cochlear nerve – this nerve joins the vestibular nerve to become the vestibulocochlear nerve (CN VIII) and travels through the internal acoustic meatus with CN VII into the cranial cavity to the brainstem. (4) Cochlea, (5) vestibule housing the saccule and utricle, (6) semicircular canals, (7) ear ossicles, (8) tympanic membrane, and (9) horizontal portion of the external ear canal. (B) Inner ear and cochlear anatomy. *Source:* Created with www.biorender.com.

The hearing system involves the sensory receptor organ (organ of Corti) within the cochlea of the inner ear (Figure 1.6B). The neurons forming the cochlear branch of CN VIII have their cell bodies in the spiral ganglion of CN VIII. They receive impulses from the neuroepithelial hair cells of the organ of Corti and enter the brainstem and synapse with the cochlear nuclei. The auditory information is transmitted through bilateral ascending auditory pathways to the medial geniculate nucleus of the thalamus via the lateral lemniscus. From this nucleus, a third neuron projects via the auditory radiation to the contralateral auditory cortex.

Clinical evaluation: Observation of the animal's body and head posture at rest, and evaluation of its gait, can provide significant information about the vestibular function of CN VIII. This function can also be more specifically assessed by testing the vestibulo-ocular reflex (also known as physiological nystagmus; "Physiological Nystagmus" video 1.15). This type of nystagmus (also called "jerk" nystagmus) is an involuntary rhythmic movement of the eyes, which typically presents with a slow phase in one direction and a quick phase in the other direction. It can occur in normal animals (physiological or vestibular nystagmus) or may be associated with an underlying abnormality (pathological nystagmus). The direction of the nystagmus is classically described by that of the fast-phase movement. A physiological nystagmus can be induced in normal individuals by lateral rotation of the head. With a feline patient, this is best done by holding the animal at arm's length and rotating it from side to side. This physiological nystagmus stabilizes images on the retina during head movement. It is always observed in the plane of head rotation and consists of a slow phase in the direction opposite to head rotation and a fast phase in the same direction. In the absence of any head movement, nystagmus should never be present in a normal animal.

The auditory function of CN VIII is difficult to assess clinically. The startle reaction involves observing the animal's response to a noise stimulus (e.g. a handclap or whistle). Unilateral or partial deafness is virtually impossible to detect using this test. The best assessment is the animal's response to noise when asleep: most owners can report whether they have to touch their animal to wake them. Electrophysiological assessment (such as the brainstem auditory evoked response test) is necessary to confirm and assess the severity of the hearing loss.

Clinical signs of dysfunction: Vestibular dysfunction may result in any or all of the following clinical signs: head tilt, falling, leaning, rolling, circling, abnormal and/or positional nystagmus, positional strabismus, and asymmetrical ataxia. Clinical signs may be a result of lesions involving the receptor organs in the inner ear or the vestibular portion of CN VIII (e.g. peripheral vestibular dysfunction) or lesions involving the brainstem vestibular nuclei (e.g. central vestibular dysfunction). Less frequently, lesions affecting the caudal cerebellar peduncle, the fastigial nucleus, or the flocculonodular lobes of the cerebellum can cause central vestibular dysfunction with a resulting paradoxical head tilt. Bilateral vestibular disease is characterized by head sway from side to side, loss of balance on both sides, and symmetrical ataxia with a wide-based stance. A physiological nystagmus cannot be elicited.

The presence of spontaneous or positional jerk nystagmus indicates vestibular dysfunction but does not further localize the lesion to the peripheral or central vestibular system. Some exceptions are worth mentioning:

- Positional, spontaneous, and physiological nystagmus are usually absent with bilateral lesions.
- Vertical nystagmus and nystagmus that changes direction with different head positions are most commonly seen with central lesions.

GLOSSOPHARYNGEAL AND VAGUS NERVES – CN IX AND CN X

Anatomy and function: The glossopharyngeal and vagus nerves share sensory (nucleus tractus solitarius) and motor (nucleus ambiguus) nuclei. CN IX innervates the musculature of the pharynx and palatine structures. It provides sensory innervation to the caudal third of the tongue and pharyngeal mucosa (taste). Its parasympathetic component innervates the parotid and zygomatic salivary glands. CN X controls motor function of the larynx (recurrent laryngeal branch), pharynx, and esophagus (the cervical esophagus is innervated by the pharyngeal and recurrent laryngeal branches, while the thoracic esophagus is innervated by the vagal branches). It provides sensory function to the larynx, pharynx, and thoracic and abdominal viscera. Its parasympathetic component provides innervation to all thoracic and abdominal viscera, except those of the pelvic region. Both nerves leave the skull through the jugular foramen continuing into the tympano-occipital fissure which lies behind the osseous bulla.

Clinical evaluation: The pharyngeal (swallowing or gag) reflex can assess the function of CN IX and CN X. It is evaluated by applying external pressure to the hyoid bones to stimulate swallowing or by stimulating the pharynx with a finger to elicit a gag reflex. It can also be evaluated by watching the animal eat or drink or by opening its mouth wide; the animal will usually close its mouth, swallow, and lick its nose, allowing simultaneous evaluation of the tongue. The parasympathetic portion of CN X can be evaluated by testing the oculocardiac reflex. This is achieved by applying digital pressure to both eyeballs and observing simultaneously a reflex bradycardia (also mediated by CN V).

Clinical signs of dysfunction: CN IX dysfunction results in dysphagia, absent gag reflex, and reduced pharyngeal tone. Animals frequently cough after drinking and swallow repeatedly because of an accumulation of saliva in their pharynx. CN X dysfunction results in dysphagia, inspiratory dyspnea (due to laryngeal paralysis), voice changes (dysphonia), and regurgitation (due to megaesophagus in the case of a bilateral vagal disorder). The pharyngeal and oculocardiac reflexes are absent.

ACCESSORY NERVE – CN XI

Anatomy and function: CN XI provides motor innervation to the trapezius and part of the sternocephalicus and brachiocephalicus muscles. It leaves the skull with CNs IX and X.

Clinical signs of dysfunction: Lesions of this nerve result in trapezius muscle atrophy. The neck may be deviated toward the affected side in chronic cases. Isolated lesions of the accessory nerve are an extremely rare finding.

HYPOGLOSSAL NERVE – CN XII

Anatomy and function: CN XII provides motor innervation to the muscles of the tongue. The nucleus is in the caudal medulla and can therefore be affected by cervical lesions located cranially. This cranial nerve exits the skull by the hypoglossal canal foramen.

Clinical evaluation: CN XII function can be evaluated by inspecting the tongue for atrophy, asymmetry, or deviation to one side. Manually stretching the tongue and observing a voluntary retraction assesses the tongue's tone. Applying food paste to the nose and observing the animal licking assesses the tongue's movement, as does watching it prehend food or drink water from a clear, colorless bowl.

Clinical signs of dysfunction: Lesions affecting CN XII can result in problems with prehension, mastication, and deglutition. With unilateral and recent lesions, the tongue tends to deviate

toward the contralateral side. With unilateral and chronic lesions, the tongue protrudes toward the side of the lesion, and atrophy is observed ipsilaterally. Muscle fasciculations may be obvious on the affected side in the denervated tongue.

SPINAL REFLEXES

Spinal reflexes evaluate reflex arcs and can provide information about the influence of descending UMN pathways. A reflex arc consists of an afferent sensory nerve that synapses directly or indirectly with an efferent motor nerve. The synapse for a given spinal reflex occurs within specific spinal cord segments.

Spinal Cord Reflex Grading

Spinal cord reflexes are graded as absent, weak (present but reduced), normal, exaggerated, and clonic.

Causes of absent and weak reflexes include a lesion affecting any part along the local reflex arc (afferent sensory component, spinal cord segment, efferent motor component). Reflexes can be difficult to assess in patients with severe limb rigidity, range of motion, or muscle extension (either due to loss of UMN inhibition or due to fibrosis of a joint or muscle).

Causes of exaggerated reflexes and clonus include a UMN lesion in the spinal cord cranial to the spinal cord segment involved in the reflex. In testing the patellar reflex, an exaggerated response, called pseudohyperreflexia, can also be seen with lesions in the L6–S1 region of the spinal cord. This region is the source of efferent motor neurons to the stifle flexors that ordinarily dampen stifle extension during the patellar reflex. This patellar pseudohyperreflexia is accompanied by a decreased pelvic limb withdrawal reflex.

Ideally, spinal reflexes should be performed with the patient in lateral recumbency. If this is not possible, the withdrawal reflexes and the patellar reflex can be performed with the patient standing with adequate support provided, but beware that it can be difficult to isolate spinal reflex activity in patients that resist or lose their balance. The perineal reflex can be performed with the patient in any position. The cutaneous trunci reflex is generally performed with the patient standing or sitting.

Thoracic Limb Spinal Reflex Testing

The spinal cord segments for thoracic limb spinal reflexes are C6–T2. Although an exhaustive list of thoracic limb reflex testing is provided subsequently, the authors generally limit their testing to the withdrawal reflex, as it reliably provides sufficient information to assess the nerves and spinal cord segments pertinent to thoracic limb reflex arc evaluation.

Withdrawal (Flexor) Reflex

Anatomy: (Figure 1.7)

- Afferent, sensory nerves: Median nerve, ulnar nerve, and radial nerve
- Spinal cord segments: C6–T2
- Efferent, motor nerves: Median nerve, ulnar nerve, musculocutaneous nerve, and axillary nerve

Clinical evaluation: To perform the withdrawal reflex, use your fingers to pinch the webbing between toes or pinch a digit on the upper limb (do not attempt to perform the withdrawal reflex on the limb touching the ground) (Video 1.18). If you do not observe the reflex with a light pinch, you might need to pinch harder. With an intact reflex, you will observe flexion at every joint (shoulder, elbow, and carpus) in conjunction with the pinching stimulus.

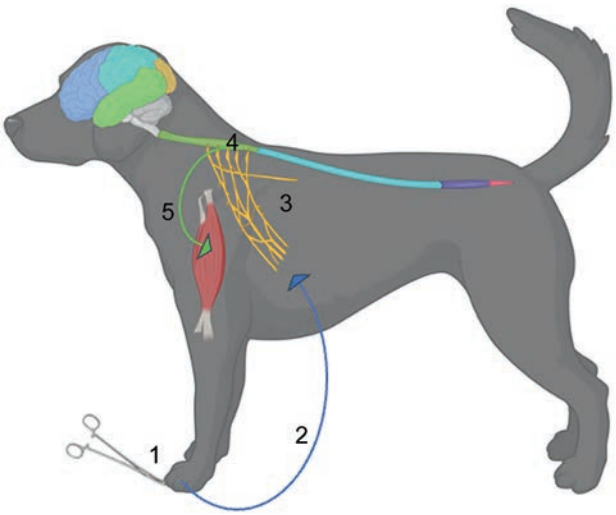

FIGURE 1.7 An illustration of the flexor withdrawal reflex anatomy of the thoracic limb. (1) Nociceptors are stimulated in the digits; (2) sensory input through the median, ulnar, and radial nerves (depending on where the noxious stimulus is applied) and travels through the brachial plexus (3) to the C6–T2 spinal cord segments (4). Motor output is then through the nerve roots of the axillary, musculocutaneous, median, and ulnar nerves (5) to the flexor muscles of the limb. *Source:* Created with www.biorender.com.

VIDEO 1.18 A flexor withdrawal reflex is often performed with the patient in lateral recumbency and initiated with a noxious stimulus to the digits. The entire limb should be withdrawn to the body with good strength, and there should be complete flexion of the carpus and elbow visible.

Biceps Tendon Reflex

Anatomy:

- Afferent, sensory nerve: Musculocutaneous nerve
- Spinal cord segments: C6–C8
- Efferent, motor nerve: Musculocutaneous nerve

Clinical evaluation: To perform the biceps reflex, gently extend the upper limb at the level of the shoulder and the elbow. Place your thumb at the cranial aspect of the elbow joint over the tendon of insertion for the biceps reflex. Using a reflex hammer, gently strike your thumb. In an intact reflex, you will observe a slight contraction of the biceps muscle in conjunction with striking your thumb. However, this reflex is difficult to elicit/not always present in normal dogs and cats, and is challenging to visualize in long-haired animals.

Triceps Tendon Reflex

Anatomy:

- Afferent, sensory nerve: Radial nerve
- Spinal cord segments: C7–T2
- Efferent, motor nerve: Radial nerve

Clinical evaluation: To perform the triceps reflex, hold the upper antebrachium and gently internally rotate it and flex the elbow to expose the tendon of insertion for the triceps reflex on the caudal aspect of the elbow. Using the blunt end of a reflex hammer, gently strike the tendon. In an intact reflex, you will observe a slight contraction of the triceps muscle in conjunction with striking the tendon. However, this reflex is difficult to elicit/not always present, even in normal dogs and cats.

Extensor Carpi Radialis Reflex

Anatomy:

- Afferent, sensory nerve: Radial nerve
- Spinal cord segments: C7–T2
- Efferent, motor nerve: Radial nerve

Clinical evaluation: To perform the extensor carpi radialis reflex, place one hand underneath the upper elbow to provide support. Use the pointed end of a reflex hammer to gently strike the extensor carpi radialis muscle at its origin. In an intact reflex, you will observe carpal extension in conjunction with striking the muscle. This reflex is difficult to elicit/not always present, even in normal dogs and cats. This may not be a true myotatic reflex, though, as it can be elicited in dogs that have had their radial nerves transected.

Pelvic Limb Spinal Reflex Testing

The spinal cord segments for pelvic limb spinal reflexes are the L4–S1 segments of the spinal cord. Although an exhaustive list of pelvic limb reflex testing is provided subsequently, the authors generally limit their pelvic limb reflex testing to the patellar and withdrawal reflexes, as they reliably provide sufficient information for assessing the nerves and spinal cord segments pertinent to pelvic limb reflex arc evaluation.

Patellar Reflex

Anatomy: (Figure 1.8)

- Afferent, sensory nerve: Femoral nerve
- Spinal cord segments: L4–L6
- Efferent, motor nerve: Femoral nerve

Clinical evaluation: To perform the patellar reflex, place one hand underneath the upper limb to provide support. The limb should be held in gentle flexion. Using the blunt end of a reflex hammer, gently strike the patellar tendon. In an intact reflex, you will observe stifle extension in conjunction with striking the tendon (Videos 1.19 and 1.20). Occasionally, the patellar reflex is absent in the limb when it is upright. The patellar reflex is the only reflex that can be performed on the dependent limb and can sometimes be present in this position despite being absent in the upper limb. A subset of normal, geriatric dogs lack patellar reflexes despite having normal femoral nerve and L4–L6 spinal cord segment function.



VIDEO 1.19 The patella reflex is performed by striking the patella tendon when the animal is in lateral recumbency, with the stifle slightly flexed. The response should be a brisk extension of the limb due to a reflex contraction of the quadriceps muscle.



VIDEO 1.20 A dog with acute flaccid paralysis and Schiff–Sherrington exhibits reduced to absent pelvic limb patella and flexor withdrawal reflexes.

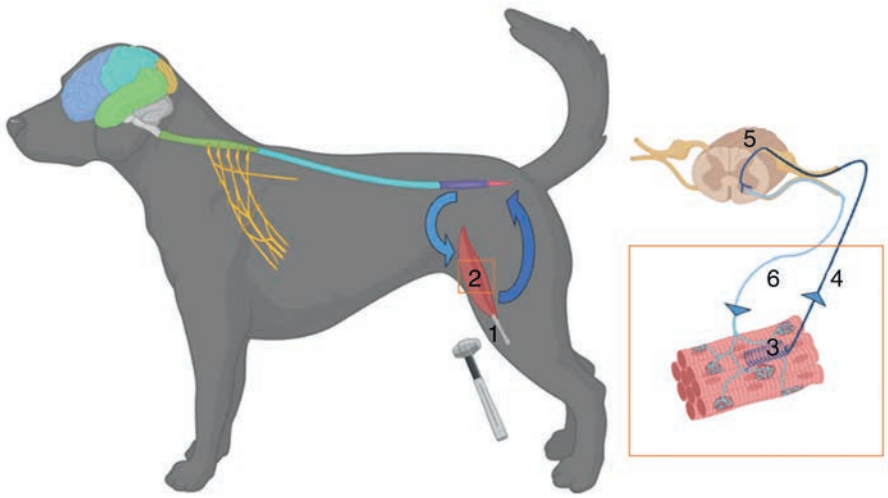

FIGURE 1.8 An illustration of the neuroanatomy responsible for the patella reflex. (1) The patella tendon is struck, which causes contraction of the quadriceps muscle (2) by indirectly stretching the muscle spindles (3), which activate the 1A afferent fibers (4) sending a sensory message to the L4–L6 spinal cord segments (5). The sensory fibers synapse directly onto the motor neurons (6) of the femoral nerve. *Source:* Created with www.biorender.com.

Withdrawal (Flexor) Reflex

Anatomy:

- Afferent, sensory nerve: Sciatic nerve
- Spinal cord segments: L6–S1
- Efferent, motor nerve: Sciatic nerve

Clinical evaluation: To perform the withdrawal reflex, use your fingers to pinch the webbing between digits 4 and 5 or the fifth digit on the upper limb (do not attempt to perform the withdrawal reflex on the limb touching the ground). Afferent information from the dorsal aspect of this digit is carried via the cutaneous branches of the fibular nerve, and information from the plantar aspect is carried via the cutaneous branches of the tibial nerve. If you do not observe the reflex with a light pinch, you might need to pinch harder. In an intact reflex, you will observe flexion at every joint (hip, stifle, tarsus) in conjunction with the pinching stimulus.

The flexion of all joints in the pelvic limb is mediated via the sciatic nerve, with the exception of the hip. The main flexors of the hip are the iliopsoas muscle and the rectus femoris. Both receive efferent innervation from the femoral nerve, which originates from the L4–L6 spinal cord segments. The iliopsoas muscle is also innervated by all of the nerves originating from the lumbar spinal cord segments cranial to L4. The skin of the first digit is innervated by cutaneous branches of the saphenous nerve branch of the femoral nerve. In patients with complete sciatic dysfunction, they will lack the ability to flex the stifle and the hock (and will lack sensation) when the fifth digit is pinched but will flex the hip when the first digit is pinched.

Cranial Tibial Reflex

Anatomy:

- Afferent, sensory nerve: Fibular nerve (branch of the sciatic nerve)

- Spinal cord segments: L6–L7
- Efferent, motor nerve: Fibular nerve

Clinical evaluation: To perform the cranial tibial reflex, gently support the upper pelvic limb. Using the pointed end of a reflex hammer, gently strike the muscles running along the cranial tibia. In an intact reflex, you will observe slight tarsal flexion. However, this reflex is difficult to elicit/not always present, even in normal dogs and cats. Like the extensor carpi radialis reflex, this also might not be a true reflex.

Gastrocnemius Reflex

Anatomy:

- Afferent, sensory nerve: Tibial nerve (branch of the sciatic nerve)
- Spinal cord segments: L7–S1
- Efferent, motor nerve: Tibial nerve

Clinical evaluation: To perform the gastrocnemius reflex, gently grasp the metatarsal region and flex and internally rotate the tarsus to expose the common calcaneal tendon. Using the blunt end of a reflex hammer, strike the tendon. In an intact reflex, you will observe a slight extension of the tarsus, and you may also observe a brief twitch of the caudal thigh muscles. However, this reflex is difficult to elicit/not always present, even in normal dogs and cats.

Other Segmental Spinal Reflexes

Cutaneous Trunci Muscle Reflex

Anatomy:

- Afferent, sensory nerves: segmental spinal nerves of T2–L5
- Spinal cord segments: C8–T1
- Efferent, motor nerve: Lateral thoracic nerve

Clinical evaluation: To perform the cutaneous trunci muscle reflex, use a pair of hemostats to lightly pinch the skin. Start on one side at the level of the wing of the ilium, slightly off midline. In an intact reflex, you will observe the skin over both sides of the thorax twitch (Video 1.21). If you do not observe this reflex at this level, then continue to pinch skin more progressively further cranially until the reflex is observed, or until you reach the cervicothoracic junction. The location at which the cutaneous trunci reflex is observed is called the "cutaneous trunci cutoff" (Video 1.22). Once you determine the cutaneous trunci cutoff on one side, repeat on the other side.



VIDEO 1.21 The cutaneous trunci muscle reflex (formerly the panniculus reflex) is evaluated by pinching the skin on the dorsal trunk between T2 and the sixth lumbar vertebra, observing the contraction of the cutaneous trunci muscles bilaterally, which produces a twitch in the overlying skin as seen in this normal dog.



VIDEO 1.22 An English bulldog exhibits an absent cutaneous trunci muscle (panniculus) reflex bilaterally until the skin is pinched on the left side in the cranial thoracic region. This indicates a lesion is likely immediately cranial to the site.

This reflex involves segmental spinal nerves that carry sensory information into the spinal cord at approximately the level being pinched from its most caudal aspect over the L6 vertebral body. An interneuron travels from the segment cranially on both sides of the spinal cord to synapse

with the motor neuron cell bodies, which are located in the ventral horns of the spinal cord in segments C8–T1. These motor neurons comprise the lateral thoracic nerve, which innervates the cutaneous trunci muscle. Because the impulse travels to both sides, pinching the skin on one side will lead to bilateral contraction of the cutaneous trunci muscles. The caudal extent for which the reflex can be elicited varies in dogs. In most normal dogs, the cutaneous trunci reflex begins at the level of the L6 vertebra. This reflex is not always reliably elicited, even in normal dogs, and is difficult to elicit in cats. Gently pulling on a small bunch of fur rather than pinching the skin may be more effective in cats.

Perineal Reflex

Anatomy:

- Afferent, sensory nerve: Pudendal nerve
- Spinal cord segments: S1–S3
- Efferent, motor nerve: Pudendal nerve

Clinical evaluation: To perform the perineal reflex, gently pinch the skin of the perineal region using a hemostat on both sides. In an intact reflex, you will observe immediate tail flexion and contraction of the external anal sphincter.

Head and Spinal Palpation

Palpation of the head is useful in finding masses, muscle atrophy, pain, persistent fontanelles, and abnormal skull conformation. In addition to palpating for masses, gently retropulse each eye to check for discomfort and/or retrobulbar mass effects. Palpate the temporalis muscles to look for either unilateral or bilateral atrophy. Gently open the mouth to assess for any pain associated with the temporomandibular joints, decreased range of motion, or decreased jaw tone. To check for a persistent fontanelle, gently palpate the dorsal-most aspect of the skull. Persistent fontanelles may be accompanied by a domed head that extends laterally past the zygomatic arches in dogs and cats with hydrocephalus. Pressing on the skull slightly dorsal to the zygomatic arches can sometimes lead to a painful response in animals with structural brain disease.

Palpation of the vertebral column is useful for detecting painful regions, masses, epaxial muscle atrophy, swelling, and abnormal vertebral curvature (e.g. kyphosis or scoliosis). Palpation and range of motion assessments are generally performed at the end of the neurological examination, since they are capable of inducing discomfort that may make the animal more difficult to examine further. Generally, if a region is suspected to be painful based on the patient's history and posture, it should be evaluated last. To palpate the thoracolumbar vertebral column, place the dominant hand over the patient's back, and use the nondominant hand to apply light counter support ventral to the thorax/abdomen. Avoid pushing dorsally on the abdomen, as this can reveal abdominal pain that may be confused as back pain. If no pain develops with light palpation, then proceed with stronger palpation. Place one finger or knuckle on either side of the midline, and gently apply pressure ventrally *in between spinous processes*, and travel cranially or caudally. To check for lumbosacral pain, place one hand ventral to the pelvis to extend the lumbosacral joint, raise the pelvis, and use your other hand to apply pressure ventrally over the L7. Performing the tail range of motion can also help in disclosing lumbosacral discomfort. Subtle evidence of thoracolumbar/lumbosacral pain or discomfort may consist of mild abdominal/epaxial muscle tensing. More overt evidence may include vocalizations, the patient trying to bite/escape.

In dogs or cats with obvious signs of neck pain (low head carriage, cervical muscle fasciculations), cervical palpation can be skipped. To palpate the cervical vertebral column, place one hand on either side of the dog's neck and palpate the articular processes. Direct pressure toward midline, working caudally to cranially from the cervicothoracic junction to the craniocervical junction. If no overt evidence of neck pain is observed with palpation, then cervical range of motion can be performed to assess for neck pain. Turn the patient's head toward either side. A normal dog or cat can touch its nose to its lateral thorax. Extending the head upward is also acceptable. The authors advise against flexing the neck ventrally, as this maneuver can lead to exacerbation of neurological dysfunction in patients with abnormal atlantoaxial joints. In cases where patient disposition precludes performing cervical range of motion, a treat can be waved slowly in front of the patient to see if it turns its neck to track it. Subtle evidence of cervical pain may consist of cervical muscle fasciculations or tensing during palpation or reluctance to have the head moved in one or multiple directions. More overt evidence may consist of vocalization/the patient trying to bite/escape or exacerbation of a thoracic limb nerve root signature.

NOCICEPTION TESTING

For pain to be perceived consciously, the sensory component of the peripheral nerves and their spinal cord segments, the spinal cord and brainstem and the related thalamocortex system must all be intact and functional (Figure 1.9). The nociceptive fibers are located deep in the spinal cord white matter and project to both sides of the spinal cord, forming a multisynaptic bilateral network. Therefore, only a severe bilateral spinal cord lesion impairs nociception in cases of

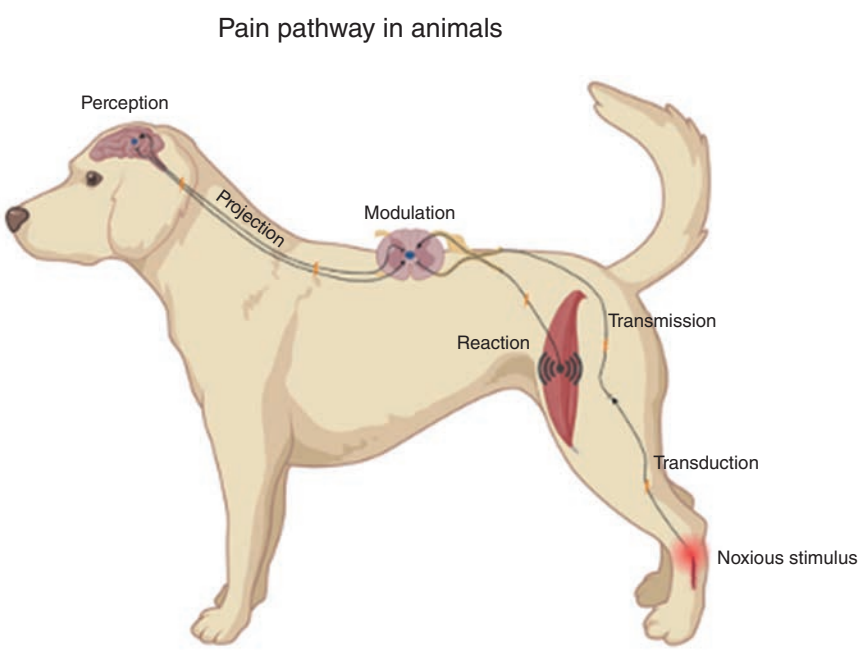

FIGURE 1.9 An illustration of the pain pathways in a dog and the mechanisms of transmission.
Source: Created with www.biorender.com.

spinal cord dysfunction, or severe damage to a nerve in the periphery for patients displaying monoplegia. For this reason, nociception testing is a useful prognostic indicator in cases of disease. Pain perception must be assessed in any region demonstrating plegia (limb(s), tail, and the perineal region). The expected reaction is a behavioral response such as turning the head, trying to bite, or vocalization. The animal is placed on its side, ideally with a second person talking to it or stroking it to distract its attention. A gentle squeeze is applied initially to the digits to elicit the withdrawal reflex. If the animal does not exhibit a behavioral response to a gentle squeeze, heavy pressure is then applied.

Withdrawal of the limb is only the flexor reflex and should not be taken as evidence of pain sensation. Other areas of cutaneous sensory testing are the tail, perineum, and perianal region, as well as the cutaneous sensory distribution of the thoracic and pelvic limb nerves.